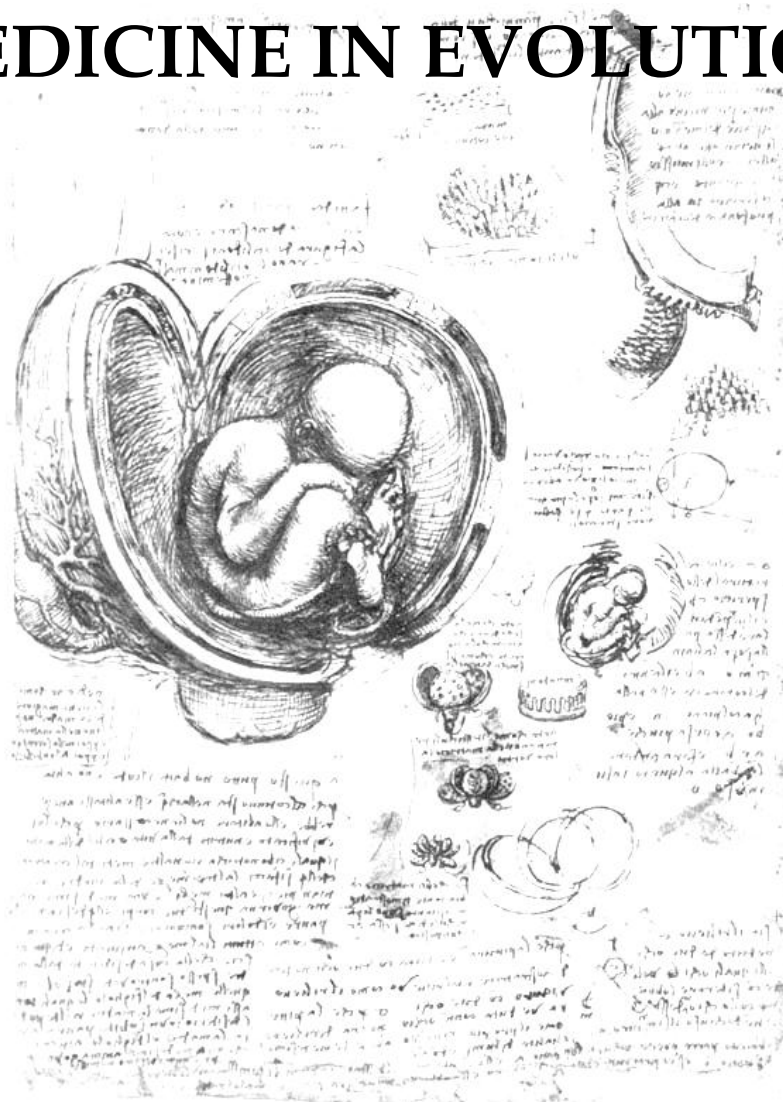

Volume XXI, Nr. 2, 2015, Timișoara, Romania
ISSN 2065-376X

SUPPLEMENT

MEDICINE IN EVOLUTION



**CENTER OF PROMOTING HEALTH EDUCATION AND
MOTIVATION FOR PREVENTION IN DENTISTRY
CENTER FOR CONTINUOUS MEDICAL EDUCATION**

medicineinevolution.umft.ro

Journal edited with the support of

ROLF MARUHN
GERMAN CONSUL TO TIMISOARA
&



Printed at: WALDPRESS, Timisoara,
17 Brandusei Street,
Phone/Fax: 0040256422247

Edited at: EUROSTAMPA, Timisoara
26, Revolutiei 1989 Street,
Phone: 0040256204816

OPEN GATES TO THE FUTURE

National Conference of Infectious Diseases 28-30 May 2015 Timisoara, Romania

Scientific Reviewers:

Prof. Univ. Dr. Adrian Streinu-Cercel

University of Medicine and Pharmacy "Carol Davila" București

Editor

Voichița Lăzureanu

Mădălina Coccoceanu

CONTENTS

ARTICLES

ABSTRACTS

VOICHITA LAZUREANU UNDERSTANDING AND DETECTION OF ANTIRETROVIRAL RESISTENCE KEY TO PROPER CART	1
LUCIAN NEGRUTIU, DANA MARTI THE EFFICACY OF STATINS IN SOME INFECTIOUS DISEASES	2
DUMITRU CÂRSTINA, J. CRISTIAN THE INFLUENZA: HISTORY AND PRESENT	3
ERZSÉBET IRINGÓ ZAHARIA KÉZDI, CARMEN CHIRIAC, NINA ȘINCU, ANDREA BODEA, E. DÉZSI, ANDREA INCZE MONOTHERAPY – EFFICIENT ANTIRETROVIRAL THERAPY EVEN AFTER THREE YARS: CASE REPORT	4
ADRIAN O. ABAGIU, ALICE ATOMOAIE, FLORENTINA PARASCHIV, ELENA D. BUNESCU, GEORGETA PREDĂ, GABRIEL A. POPESCU, MĂDĂLINA SIMOIU, DAN OTELEA, SIMONA PARASCHIV, RODICA GRUIA, FLORIN M. DUNA PARTICULARITIES OF HIV AND HCV INFECTIONS IN ADDICTS IN OPIOID SUBSTITUTION THERAPY (OST)	5
MANUELA ARBUNE CHARACTERISTICS OF CLOSTRIDIUM DIFFICILE INFECTION IN PATIENTS WITH TUBERCULOSIS	6
MANUELA ARBUNE, KAMEL EARAR, DOINA-CARINA VOINESCU, MADALINA MATEI ORAL HEALTH IN HIV INFECTED PATIENTS - TRANSDISCIPLINARY APPROACHES	7
MIHAELA CĂTĂLINA LUCA, IRINA TEODORESCU, ELENA DUCA, ELISABETA BUZOI, IOANA ALEXA, A. ST. LUCA CLINICAL AND EPIDEMIOLOGICAL CONSIDERATIONS IN ACUTE VIRAL HEPATITIS A IN 2014	8
MANUELA CURESCU, BIANCA CERBU TREATMENT IN CHRONIC C HEPATITIS- PAST, PRESENT AND FUTURE	9
DANIELA BIRIS, TEODORA MOISIL, VOICHITA-ELENA LAZUREANU TRUTH OR SECRET?	10

DANA NEGRU, VICTOR TOMA, IOANA JURCĂ, GHEORGHE NINI, LILIANA BRAN, MARIANA NAGY EVOLUTION OF VACCINES AND THEIR EFFECTIVENESS, FROM THE FIRST ATTEMPTS UNTIL TODAY, ARAD COUNTY EXPERIENCE	11
DANIELA T. MARȚI, RUJIȚA CIUREA, L.NEGRUȚIU, SIMONA TALPEȘ VALUES OF BACTERIOLOGICAL INVESTIGATION IN URINARY TRACT INFECTIONS AT INFANTS	12
RUXANDRA LAZA, ALEXANDRU CRIȘAN, NARCISA NICOLESCU, ADELINA MARINESCU, LUCI ROTAR IMPLICATIONS OF THE ROTAVIRUSES IN ACUTE DIARRHEA	13
GHEORGHE JUGULETE FECAL MICROBIOTA TRANSPLANTATION IN CHILDREN WITH RECURRENT CLOSTRIDIUM DIFFICILE INFECTION	14
ANDREI VĂȚĂ, IOANA ALINA ALEXA, ELENA DUCA, FLORIN ROȘU, CĂTĂLINA MIHAELA LUCA CHARACTERISTICS OF THE 2014-2015 INFLUENZA SEASON IN THE INFECTIOUS DISEASES HOSPITAL OF IASI	15
GABRIELA-CORNELIA HOROSANU PREDICTION MODEL FOR CHRONIC KIDNEY DISEASE IN HIV PATIENTS	16
LARGU MARIA ALEXANDRA, LEBĂDĂ A., PRISĂCARIU L., NICOLAU CRISTINA, MANCIUC DOINA CARMEN THE PSYCHOLOGICAL APPROACH – ESSENTIAL ASPECT OF THE PATIENT MANAGEMENT IN HIV/AIDS - CASE REPORT	17
SIMONA ERSCOIU, I. C. POPA, OLIVIA BURCOS, GRATIELA TARDEI, MARIA NICA, E.CEAUSU CLINICAL, IMUNOLOGICAL AND VIROLOGICAL PROFILE OF PATIENTS NEWLY DIAGNOSED WITH HIV INFECTION IN A YEAR OF REFERENCE	18
VALERIU GHEORGHITA, RAZVAN HAINAROSIE, ALINA ELENA BARBU, RAZVAN VASILESCU, ELIZA GRAMADA, CLAUDIU SOCOLIUC, MONA POPOIU, RUXANDRA MOROTI, FLORIN ALEXANDRU CARUNTU DIAGNOSTIC AND THERAPEUTIC CHALLENGES IN THE MANAGEMENT OF MUCORMYCOSIS: PRESENTATION OF TWO CLINICAL CASES	19
ALEXANDRU CRIȘAN, LUCI ROTAR, ADELINA MARINESCU, NARCISA NICOLESCU, RUXANDRA LAZA BILIODIGESTIVE FISTULA – RARE CAUSE FOR PROLONGED FEVER SYNDROME. CLINICAL CASE PRESENTATION	20
BIANCA CERBU, MANUELA CURESCU, DOGARU DELIA, IOSIF MARINCU SEVERE ACUTE LIVER FAILURE IN A PATIENT WITH LIVER CIRRHOSIS HBV AND HDV	21

OVIDIU ROSCA, ANDREEA ARDELEANU, MONICA CIALMA, DANIELA MIHALCEA, VALERIA BICA, CAMELIA NIȚĂ, IOSIF MARINCU DISEMINATED CRYPTOCOCCOSIS IN A HIV LATE PRESENTER PATIENT	22
VALERIU GHEORGHITA, ALINA ELENA BARBU, MONICA LIVIA GHEORGHIU, FLORIN ALEXANDRU CARUNTU, ADRIAN STREINU-CERCEL, RUXANDRA MOROTI THYROID DYSFUNCTION IN SEPSIS: CORRELATION WITH SEVERITY AND FINAL OUTCOME IN A PROSPECTIVE STUDY	23
NARCISA NICOLESCU, ALEXANDRU CRIȘAN, EMILIA NICOARĂ, VOICHIȚA LĂZUREANU, RUXANDRA LAZA, VIRGIL MUSTA, ADELINA MARINESCU ANTI-MEASLES VACCINATION – PRO AND AGAINST	24
SIMONA CLAUDIA CAMBREA, ANA-MARIA-IANCU, SORINA CARP, MARIA MARGARETA ILIE CLINICAL AND EPIDEMIOLOGICAL ASPECTS OF INFLUENZA IN CHILDREN HOSPITALIZED BETWEEN NOVEMBER 2014 – MARS 2015 IN THE CLINICAL HOSPITAL OF INFECTIOUS DISEASES OF CONSTANTA COUNTY	25
MARIANA MARDARESCU, ADRIAN STREINU-CERCEL, CRISTINA PETRE, MARIETA IANCU, SANDA VINTILA, DANIELA VITELARU, CLAUDIU SCHIOPU SURVEILLANCE OF THE HIV PERINATALLY EXPOSED CHILD IN ROMANIA	26
CRISTIANA OPREA TREATMENT OF HIV-TB CO-INFECTION: AN OVERVIEW	27
IOSIF MARINCU, CLAUDIA CAMBREA, ȘTEFAN MIHĂICUȚĂ, SORINA LAITIN, ȘTEFAN FREȚ, NICOLETA BERTICI, PATRICIA POPTELECAN, VALERIA BICA, LIVIUS ȚÎRNEA ALGORITHM MONITORING OF PATIENTS WITH HIV/AIDS FOR DETECTING OF PULMONARY TUBERCULOSIS	28
MIOARA PREDESCU NORWEGIAN FINANCIAL MECHANISM 2009 – 2014	29

POSTER SESSION

ANDREEA BODEA-ALUCĂI, ANCA GEORGESCU, ELOD NAGY, CARMEN CHIRIAC, NINA ȘINCU, VALENTIN BODEA URINARY TRACT INFECTIONS: ETIOLOGIC SPECTRUM AND SUSCEPTIBILITY TO ANTIBIOTICS	30
ANA LUPU, RAMONA TALE, RAMONA STANCULETE, MIHAELA CAMELIA EPURE, ALINA MARILENA LAZARESCU, VOICHITA LAZUREANU THE ASSOCIATION OF PULMONARY TUBERCULOSIS IN A PATIENT WITH HIV INFECTION. CASE REPORT	31
CARMEN CHIRIAC, IRINGO ZAHARIA-KEZDI, BRÎNDUSA ȚILEA, ANCA GEORGESCU, CRISTINA GÎRBOVAN, ANDREA INCZE, NINA ȘINCU, MANUELA CUCEREA RISK OF MOTHER-TO-CHILD TRANSMISSION OF HIV	32
OTTILIA DIMENY, IOANA-RALUCA TODORAN, ZS. RAJNA, E. DEZSI, KATALIN PUSOK, ERZSEBET-IRINGO ZAHARIA-KEZDI OPPORTUNISTIC INFECTIONS AND IMMUNE RECONSTITUTION INFLAMMATORY SYNDROME IN A LATE PRESENTER PATIENT	33
DUMITRESCU FLORENTINA, CUPȘA A, GIUBELAN L, CUPȘA DINA MARIA, STOIAN ANDREEA CRISTINA, NICULESCU IRINA, STĂNESCU MARIANA, COROBEA ALEXANDRA SUBCLINICAL ATHEROSCLEROSIS AND THYROID CARCINOMA IN A YOUNG HIV INFECTED PATIENT-CASE REPORT	34
MIHNEA HURMUZACHE, MADALINA POPAZU, GEORGIANA ENACHE, CATALINA LUCA BENEFITS OF USING LINEZOLIDE WITH CEFTAROLINE COMPARED TO OTHERS ANTIBIOTICS ASSOCIATIONS IN SPODYLODISCITES AND PSOITES	35
MIHAELA CAMELIA EPURE, ALINA MARILENA LAZARESCU, ANA LUPU, RAMONA STANCULETE, RAMONA TALE, VOICHITA LAZUREANU INFECTIVE ENDOCARDITIS. CASE REPORT	36
MIHAELA ZAHARIA, LAURA ENE, DELIA STANCIU, CORNELIU PETRU POPESCU, SIMIN AYSEL FLORESCU, EMANOIL CEAUSU PSEUDOMONAS AERUGINOSA VENTRICULITIS – CASE REPORT	37
MIRANDOLINA PRIȘCĂ, DANA NEGRU, MARIANA NAGY TRICHINOSIS, EVOLUTIVE ASPECTS AND PARTICULAR CASES	38
RAMONA ȘTEFANIA POPESCU, RODICA BACRUBAN, ADRIAN STREINU-CERCEL LONG TERM IMMUNOSUPPRESSION AND ITS SECONDARY INFECTIOUS COMPLICATIONS IN A PATIENT WITH RHEUMATOID ARTHRITIS – CASE REPORT	39

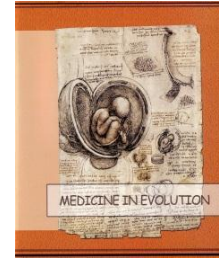
ROXANA ELENA NEMESCU, MIHNEA HURMUZACHE, CARMEN MANCIUC, CĂTĂLINA MIHAELA LUCA TREATMENT OF INVASIVE MENINGOCOCCAL DISEASE – A 18 YEAR REVIEW	40
SORINA LAITIN, I. MARINCU, E. POPOVICI, LUMINITA BADITOIU, MARIANA ANGHEL RECURRENCE FREQUENCY IN CLOSTRIDIUM DIFFICILE INFECTION IN HOSPITAL OF INFECTION DISSEAS AND NEUMOFTHISIOLOGY “V.BABES” TIMISOARA	41
VALENTINA SIMION, M.HOMOS, C. BARBULESCU, A. DOGARU, A.M.POPESCU, S. SMADU, M. NICA, EMANOIL CEAUSU OSTEODISCITIS – ETIOPATHOGENIC ASPECTS AND THERAPEUTIC MANAGEMENT	42
VALENTINA SIMION, M.HOMOS, C. BARBULESCU, A. DOGARU, A.M.POPESCU, S. SMADU, M. NICA, EMANOIL CEAUSU NOSOCOMIAL URINARY TRACT INFECTIONS – ETIOLOGY AND THERAPEUTIC MANAGEMENT	43
ZS-J. RAJNA, HELGA KATAI, FRANCISKA KRISTÁLY, D. ZAHARIA-KÉZDI, INCZE ANDREA, ERZSÉBET IRINGÓ ZAHARIA-KÉZDI APPRECIATION OF THE LIVER DAMAGE SEVERITY IN HIV-HBV COINFECTED PATIENTS	44
IOANA-RALUCA TODORAN, OTTILIA DIMENY, ZSOLT RAJNA, ANDREA INCZE, CARMEN CHIRIAC, ERZSEBET-IRINGO ZAHARIA-KEZDI DISSEMINATED TUBERCULOSIS IN A HIV PATIENT NON- ADHERENT TO ANTIRETROVIRAL THERAPY. CASE REPORT	45
DANA NEGRU, VICTOR TOMA, IOANA JURCĂ, MIRANDOLINA PRIȘCĂ, LILIANA BRAN,GHEORGHE NINI, MARIANA NAGY VERTICAL HIV TRANSMISSION IN ARAD COUNTY	46
ANDREEA ARDELEANU, OVIDIU ROSCA, DANIELA MIHALCEA, IULIANA CARAMANGIU, MONICA CIALMA, OANA PLAVITU, OANA SACEANU, PATRICIA POPTELECAN, IOSIF MARINCU ACUTE PNEUMOCOCCAL MENINGITIS IN A IMMUNOCOMPROMISED PATIENT	47
BOGDAN CATALIN TRINCA, MANUELA CURESCU, BIANCA CERBU, PATRICIA POPTELECAN, OANA SACEANU, LAURENTIU VOCHITA, VALERIA BICA, IOSIF MARINCU CEREBRAL TOXOPLASMOSIS IN A PATIENT WITH HIV/AIDS	48
ALEXANDRA ILIES, MONICA CIALMA, LOREDANA KISLINGHER, SORINA MITRESCU, MIRELA PALIU, DELIA NAN, DANIELA MIHALCEA, CAMELIA NIȚĂ, IOSIF MARINCU ACUTE LIVER FAILURE ASSOCIATED WITH ACUTE HEPATITIS B AND DRUG USE	49
IULIANA CARAMANGIU, OVIDIU ROSCA, MONICA CIALMA, SORINA MITRESCU, OANA SACEANU, ANDREEA ARDELEANU, CAMELIA NIȚĂ, IOSIF MARINCU ACUTE MENINGITIS DUE TO LISTERIA MONOCYTOGENES WITH FAVORABLE EVOLUTION	50

LOREDANA ELENA KISLINGHER, R. OPREANU, ALEXANDRA ILIES, L. VOCHITA, SORINA MITRESCU, VALERIA BICA, I. MARINCUI RECENT DIAGNOSED PULMONARY TUBERCULOSIS IN A PATIENT WITH STAGE C3 AIDS UNCOOPERATIVE	51
IOSIF MARINCUI, EMILIAN POPOVICI, PATRICIA POPTELECAN, OANA SĂCEANU, LORÉDANA KISLINGHER, SORINA MITRESCU, ALEXANDRA ILIEȘ, CAMELIA NIȚĂ, SORINA LAITIN BARTONELLA HENSELAE INFECTION WITH LYMPHATIC AND LYMPH NODAL SPREADING	52
IOSIF MARINCUI, EMILIAN POPOVICI, SORINA LAITIN, PATRICIA POPTELECAN, BOGDAN TRINȚĂ, LAURENȚIU VOCHITA, MIRELA PALIU, DOGARU DELIA, LIVIUS ȚIRNEA SEVERE HEPATIC AND RENAL FAILURE TO AN IMMUNOCOMPROMISED PATIENT WITH ACUTE HEPATITIS A	53
MIHALCEA DANIELA, MITRESCU SORINA, ROȘCA OVIDIU, ARDELEAN ANDREEA, POPTELECAN PATRICIA, ILIEȘ ALEXANDRA, SĂCEANU OANA, VALERIA BICA, IOSIF MARINCUI DISEMINATED CRYPTOCOCCOSIS IN HIV/AIDS MULTI-EXPERIENCED PATIENT	54
MIRELA PALIU, M. CURESCU, B. CERBU, S. MITRESCU, O. SACEANU, DOGARU DELIA, I. MARINCUI HEPATIC CIRRHOSIS HCV FROM A PATIENT DIAGNOSED WITH RENAL TRANSPLANTATION	55
CIALMA MONICA, ALEXANDRA ILIEȘ, OVIDIU ROSCA, OANA SĂCEANU, PATRICIA POPTELECAN, IULIA CARAMANGIU, ANDREEA ARDELEANU, IOSIF MARINCUI LIVER CANCER METASTASES IN A PATIENT WITH PROLONGED FEBRILE SYNDROME	56
OANA SACEANU, D. MIHALCEA, D. NAN, P. POPTELECAN, A. ARDELEANU, L. KISSLINGER, D. DOGARU, I. MARINCUI GROIN HERPES ZOSTER ASSOCIATED WITH RECENTLY DIAGNOSED WITH CHRONIC HEPATITIS HCV	57
PATRICIA POPTELECAN, O. ROSCA, A. ARDELEANU, I. CARAMANGIU, O. SACEANU, C. NIȚĂ, I. MARINCUI ERYSIPELAS OF THE UPPER LIMB AT A PATIENT WITH UNILATERAL MASTECTOMY	58
DUMEA RAMONA, SORINA LAITIN, POPTELECAN PATRICIA, CAMELIA NITA, OANA SACEANU, ALEXANDRA ILIES, IOSIF MARINCUI COAGULASE-NEGATIVE STAPHYLOCOCCAL SEPSIS ASSOCIATED WITH FATAL ACUTE RESPIRATORY AND HEPATIC FAILURE	59
SORINA MITRESCU, MIHALCEA DANIELA, NAN DELIA, ILIES ALEXANDRA, OANA SACEANU, PATRICIA POPTELECAN, ANDREEA ARDELEAN, PALIU MIRELA, IOSIF MARINCUI CUTANEOUS ANTHRAX IN A PATIENT WITH PROFESSIONAL RISK	60

VOCHITA LAURENTIU, OPREANU RADU, KISLINGHER LOREDANA, TRINCA BOGDAN, POPTELECAN PATRICIA, VALERIA BICA, CAMELIA NIȚĂ, MARINCU IOSIF CHRONIC HEPATITIS B VIRUS DETECTED IN AG HBS SEROCONVERSION DURING AN IMMUNOCOMPROMISED PATIENTS	61
ZAHARIA-KÉZDI ERZSÉBET IRINGÓ, CARMEN CHIRIAC, BRÎNDUȘA ȚILEA, ANCA GEORGESCU, CRISTINA GÎRBOVAN, EMESE PÁLFI THE INFECTIOUS PATHOLOGY OF THE ELDERLY IN THE EXPERIENCE OF THE CLINIC OF INFECTIOUS DISEASES I TG. MUREȘ	62
S. LAZAR, DANA OBRETIN, ADRIANA MOTOC, AUGUSTINA CULINESCU, E. CEAUSU, NICOLETA MINDU, DIANA COSTACHE THE INFLUENCE OF ANTIVIRAL THERAPY ON LIVER FIBROSIS IN HEPATITIS PATIENTS WITH HCV	63
SINZIANA DAIA, ANCA STREINU-CERCEL, OANA SANDULESCU, DANIELA OPRIS, MT DAIA, RUXANDRA IONESCU, A.STREINU-CERCEL BIOMARKERS- VALUABLE TOOLS IN DEFINING HCV SYSTEMIC INVOLVEMENT	64

ABSTRACTS

UNDERSTANDING AND DETECTION OF ANTIRETROVIRAL RESISTENCE KEY TO PROPER CART



VOICHITA LAZUREANU

University of Medicine and Pharmacy "Victor Babes" Timisoara

Replicative HIV generates in time mutants: major (primary) mutations - selected early and often have high drug specificity and minor (secondary) mutations - accumulate in viral genome already exhibiting major mutation(s). These mutations can induce resistance as follows: primary resistance - mutations in naïve patients from error-prone replication or vertical or horizontal transmission and secondary resistance – resistance selected due to drug pressure. There is also the possibility of infection with drug resistant virus. An important aspect of medication is the genetic barrier of those drugs: low genetic barrier means that loss of ART activity may be induced by one mutation (IP, NNRTI, INRT) and high genetic barrier that incremental loss of cART activity may be induced only as mutations accumulate (IP/r). Several other genetic changes altered drug sensitivity: point mutation= change in one amino-acid, an insertion= additional genetic information included, a deletion =loss of a gene fragment, recombination = exchange of genetic material by 2 viruses.

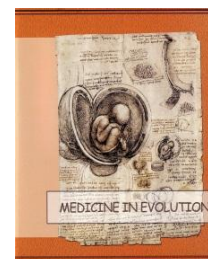Mechanisms that produce resistance to INRT are: reduced incorporation of the RTI into DNA over the normal nucleotide and excision or the hydrolytic removal of the incorporated drug or pyrophosphorylation. Mutations in response to NNRTIs decrease the binding of the drug to this pocket, through 3 mechanisms: disruption of specific contacts between the inhibitor and the NNRTI binding pocket, disruption of important interactions on the inside of the pocket and changes in the overall conformation or the size of the NNRTI binding pocket. Mutations that code for alterations of the conformational shape of IP's facilitate resistance of HIV to protease inhibitors. The locations of these mutations are primarily in the active site of the HIV protease enzyme as well as outside of the active site, including those at protease cleavage sites in the Gag-Pol polyprotein precursors. Cross-resistance is one of the major problems of protease inhibitor treatment. Integrase inhibitors select for specific resistance mutations in HIV-1 integrase. 3 pathways identified for raltegravir: N155H, Q148K/R/H, Y143C/R. Extensive cross-resistance between integrase inhibitors.

Identification of HIV mutants can be done through different resistance tests: genotype test (HIV gene sequencing of the patient's virus to detect mutations known to confer drug resistance), phenotype test (measures ability of a recombinant virus derived from the patient sample to grow in different concentrations of antiretroviral drugs), "Virtual" phenotype tests (use of genotype results to predict phenotypic susceptibility based originally on database of paired genotype and phenotype data or, more recently, through scores derived from linear regression analysis) and detection of low frequency mutations(created because standard resistance tests do not detect mutations present at low frequencies).

For a correct and complete interpretation of the resistance test we need to: collect all prior resistance tests for review, resubmit all mutations into the Stanford Resistance database and reanalyze, make sure current treatment, level of adherence, drug levels, HIV RNA, and CD4+ cell count are known, take each drug class individually and choose new regimen incorporating resistance data, treatment history, and results from clinical studies.

THE EFFICACY OF STATINS IN SOME INFECTIOUS DISEASES

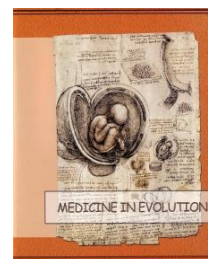
LUCIAN NEGRUTIU, DANA MARTI



Microbiology and Virology Department, Medicine Faculty, U.V.V.G. Arad

A considerable medical literature has discussed pleiotropic effects of statins on leukocyte-endothelial interaction, intra- and intercellular signaling, inflammatory gene transcription, hemoxygenase expression, and expression MHC class II antigens. In addition, anti-inflammatory and immunomodulatory properties have been shown by many other studies. Thus, statin drugs have captivated attention to have clinical significance in the preventative treatment averse to cellular damage caused by infectious agents. Furthermore, statins can reduce sepsis and infections associated complex inflammatory reactions, which is by virtue of the diverse and extrabeneficial anti-inflammatory effects that are independent of their lipid-lowering ability. The biological plausibility of a beneficial effect of statins on influenza is well established. Not long after their introduction for treatment of hypercholesterolemia, the pleiotropic anti-inflammatory properties of statins were established, followed more slowly by the appreciation that patients on statins seemed to fare better with sepsis, acute lung injury, and community-acquired pneumonia. Like many other infections, the clinical severity of influenza likely reflects the sum of damage caused by the pathogen itself and the host's inflammatory immune response. Influenza viruses are directly cytotoxic to tracheal epithelial cells, predisposing to bacterial adherence and invasion of the lower airway. However, host innate and adaptive immune responses, characterized by elevated local and systemic proinflammatory cytokines and an influx of polymorphonuclear neutrophils and lymphocytes, are thought to be of equal or greater importance in disease pathogenesis. Statins inhibit 3-hydroxy-3-methyl-glutaryl-coenzyme A reductase, the key enzyme in the mevalonate pathway leading to the production of cholesterol. This pathway also alters cell membrane signaling transduction, thereby affecting a number of immune mechanisms, including effects on B and T cells, regulatory T cells, dendritic cells, vascular endothelial cell function, and clotting. Statins are potent inhibitors of cytokine synthesis and can downregulate expression of major histocompatibility complex class II, but not class I, antigen complexes. It is likely through these interrelated effects that statins modulate the inflammatory response during some infections or influenza infection.

THE INFLUENZA: HISTORY AND PRESENT



DUMITRU CÂRSTINA, J. CRISTIAN

Clinical Hospital for Infectious Diseases, Cluj - Napoca

The complex modifications which are present in flu are due to infected cells apoptosis and uninfected cells injuries, induced by oxidative factors produced by macrophage cells and neutrophils in the organs infected with influenza virus.

In the pathogenesis of severe cases of flu are implicated a lot of factors which showed an excessive activation of innate immune response. There are evidence of high levels of cytokines on the inflammatory infiltrate from lungs and blood, facilitated the appearance and deposits of fibrin in the blood vessels, alveolus and appearance of fibrosis. There is a correlation between the level of viral load and the level of cytokines in blood and in pneumonic foci.

In the same time, it is observed a sheer increase of superoxide production which makes injuries to uninfected cells, so the treatment of severe influenza is a complex one.

The antiviral medication is directed against all sequences of life cycle of influenza virus from attachment, penetration, internalization, maturation and release.

So, there are described:

Attachment inhibitors: Sialidase (Fludase)

M2 channels inhibitors: Amantadina, Rimantadina

Endonucleases inhibitors: Flutimide

Polymerases inhibitors: Favipiravir, Ribavirine

Protease inhibitors: Ambroxol, Claritromicin

Haemagglutinin maturation inhibitors: Thiazolide

Nucleocapsid (NP) protein inhibitors: Nucleozin

Neuraminidase inhibitors (NA):

Ist generation: Zanamivir, Oseltamivir

IInd generation: Peramivir, Laninamivir

Antioxidant therapy is realized with: Superoxid dismutase, antioxidants THIOL, hydroxiantioxidants (Resveratrol), Ambroxol, Flavonoids.

In the last time it is used therapeutically schedules made by combination of antiviral which had actions in different points of influenza virus.

Also, it was resume the idea of passive immunotherapy (classics and actual with high level Ig).

MONOTHERAPY – EFFICIENT ANTIRETROVIRAL THERAPY EVEN AFTER THREE YARS: CASE REPORT



ERZSÉBET IRINGÓ ZAHARIA KÉZDI*, CARMEN CHIRIAC*, NINA ȘINCU*, ANDREA BODEA*, E. DÉZSI**, ANDREA INCZE*

*University of Medicine and Pharmacy, Tg. Mureș

**Infectious Diseases Clinic I, Tg. Mureș

The history of antiretroviral therapy (ARVT) has evolved within the past 28 years, starting from monotherapy, progressing to HAART, megaHAART, combined therapy. We learned that therapeutic success implies potent antiretroviral substances as well as patient adherence, as undesirable effects cumulate during long-term treatment. So we reached back to the starting point, again attempting monotherapy. The purpose of this paper is to present the case of the only patient treated with monotherapy in our regional center.

Material and method. Case report. Patient I.S – male, born in 1988, diagnosed with HIV infection in 1993. ARVT was initiated in 2000, for prolonged fever, with AZT+3TC+EFV, continued until 2011. Since 2012, when he started working in Tenerife, he continued ARVT with TDF+FTC+DRV/rtv.

Results. Clinical evolution under these regimens was favorable, he did not require hospital admission since 2000, he graduated highschool, started his own business as well as a family (2010 - HIV-negative wife). CD4 T-cells count increased from 206 cells/μl in 1999 to 827cells/μl in March 2012 and HIV-RNA plasma viral load remained undetectable since 2000, except 2006 when the patient ceased taking ARVT for 4 weeks and HIV-RNA plasma viral load increased temporarily to 423000 copies/μl. Afterwards he was adherent to ARVT. Since April 2012, at his own request, after counseling sessions, we reverted to monotherapy with DRV/rtv. Immunologic and virologic evolution was favorable with a 6-month CD4 T-cells count of 1354cells/μl and undetectable HIV-RNA plasma viral load. At three-year follow-up, he had 690 CD4 T-lymphocytes/μl, HIV-RNA plasma viral load undetectable. His clinical status was good over the entire period and his HIV-negative wife gave birth to their child.

Conclusions. So far, clinical, immunological and virologic outcome is good under ARV monotherapy. Monotherapy is efficient if the patient is carefully selected.

Key words: HIV, monotherapy, DRV/rtv

PARTICULARITIES OF HIV AND HCV INFECTIONS IN ADDICTS IN OPIOID SUBSTITUTION THERAPY (OST)



ADRIAN O. ABAGIU, ALICE ATOMOAIE, FLORENTINA PARASCHIV, ELENA D. BUNESCU, GEORGETA PREDA, GABRIEL A. POPESCU, MĂDĂLINA SIMOIU, DAN OTELEA, SIMONA PARASCHIV, RODICA GRUIA*, FLORIN M. DUNA

National Institute for Infectious Diseases "Prof. Dr. Matei Bals" (NIID)

***Jilava Prison Hospital (JPH)**

Objectives: After more than eight years of treating HCV and then also HIV infections in IDU's we have done a retrospective analysis on the outcomes of the treatment of this category of patients, looking also to specific epidemiologic changes in the last years in both infections.

Methods: We have analyzed the treatment files and lab data of 500 patients from Arena OST center within NIID in the last 3 years, but also 50 IDU's inmates from JPH confirmed with HIV in the last two years. The inclusion criteria were: at least three CD4 cell counts and a HIV viral load for those in treatment and one CD4 cell count for those without treatment, confirmed HCV treatment with proof of SVR or breakthrough.

Results: We have included 115 HCV patients and 97 patients with HIV/HCV co infection. From the HCV patients the majority 67% where treated before 2010 with 58% SVR, 4% non responders, 7% breakthrough's and 31% relapser's. Half of the failures where registered in the 33% of the patients treated after 2010 and here the concomitant use of legal highs might be involved. Among the co infected patients 92% had HCV infection since more than 2 years before getting HIV and 47% of those had treated the HCV infection with almost the same results 56%SVR, 33%relapser's, and 8% breakthroughs. Among the 9 patients that received HVC treatment being already co infected with HIV 8 were in ARV therapy. We found 1 non responder, 4 breakthroughs and 5 SVR, but all received only 48 weeks of treatment not 72 as in the guidelines. 45% of the HIV patients are in ARV therapy with 41% of them with at least 3 month stop in therapy and 15 % without therapy after more than 3 stops, despite the CD4 count. In those 37% adherent patients at the first treatment option only one is with high viral load but good CD4 cell count.

Discussion: The IDU population has brought significant epidemiological changes both in the HCV and HIV. So from 99% genotype 1b we have now 34% 1b, 41% 1a, 12% 3a, 7% 4d and 6% 4a. Among HIV we had 99% F subtype and now only 65% F, 29% CRF 14_BG and 6% B type.

Keywords: HIV, HCV, IDU's, OST.

CHARACTERISTICS OF CLOSTRIDIUM DIFFICILE INFECTION IN PATIENTS WITH TUBERCULOSIS



MANUELA ARBUNE

Clinical Hospital for Infectious Diseases, Galati

Background: The prevalence of Clostridium Difficile Infection (CDI) is increasing worldwide. Current epidemiology of CDI is related to the overuse of antibiotics, extended hospitalization and association of immunosuppression, but are known to have been infected community, especially in patients using proton pump inhibitors. ICD risk varies depending on the type of antibiotic use. Among tuberculosis drugs, rifampicin resistance induce the selection of CD toxemic strains and diarrhea.

Material and methods: Clinical and epidemiological characteristics of patients with CDI were collected from the medical records of Infectious Diseases Clinic (IDC) Galati. We selected the cases with simultaneous tuberculosis treatment with previous hospitalization in Pneumology Department in 2014. Diagnosis of ICD was based on evidence of CD toxin A/B.

Results: From 109 patients with CDI, 20% (22/109) were transferred from the Pneumology Department. Rifampicin treatment for tuberculosis was identified in 10/22 patients. The characteristics of the patients with CDI and tuberculosis: median age 57,5 [26; 77], pulmonary / pleural site of tuberculosis (8/10), mean time of previous exposure to rifampicin 62 days [7; 270], median value of ATLAS score 3 [3, 8], association of chronic liver disease (4/10). Vancomycin therapy was used in 9/10 patients. None patient died. The peculiarities of the cases were discussed comparative with the medical literature reports.

Conclusions: Diarrhea with CDI is rarely associated with antituberculosis medication but should be considered when rifampicin is used. Management of tuberculosis after an episode of ICD is controversial and should be individualized.

Key words: Clostridium Difficile, tuberculosis, rifampicine, diarrhea

ORAL HEALTH IN HIV INFECTED PATIENTS - TRANSDISCIPLINARY APPROACHES



MANUELA ARBUNE, KAMEL EARAR, DOINA-CARINA VOINESCU, MADALINA MATEI

Clinical Hospital for Infectious Diseases, Galati

Background: To monitor the oral status is a part of the management in HIV patients.

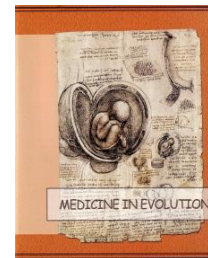Material and Methods: The cross-sectional study assessed the oral health in 114 young HIV patients from Infectious Diseases Clinic Galati. The demographic and social data were collected by interview. The OHIP-14 questionnaire assessed the quality of oral health. Standardized oral exam evaluated Decay-Missing-Fill (DMF) index and oral lesions. The data were statistically analysed.

Results: Risk factors for caries in young people with HIV are smoking and poor dental hygiene. The most common oral symptoms in HIV patients are the dry mouth and bad taste. The global OHIP-14 score was 23.45, with negative impact answers in all domains. DMF score was 10.05 and means caries high experience. All patients received at least one antiretroviral regimen. Among HIV patients, 69% experienced nadir of LCD4 < 200 / mm³, but 53.5% of patients had current LCD4 > 500 / mm³ and 48.2% are undetectable for HIV- RNA. The oral mucosal lesions were 88.6% gingivitis, 11.4% candidiasis, 12.28% marginal erythema, 4.38% hairy leukoplakia of the tongue, 4.38% gingival hypertrophy, 2.38 % bleeding, 2.38% ulcers, 1.6% polyps. The most commonly used antiretroviral drug was Ritonavir (67.5%), but no statistically significant association with oral symptoms or facial lipoatrophy was found. The frequency of facial lipoatrophy was 25.4%. Correlation of immunity (LCD4) and RNA-HIV viral load were found with DMF score, but not with OHIP-14 score.

Conclusions: The oral status of HIV youth is severely injured. Supporting programs for smoking cessation, oral health education and dental therapy for HIV patients are necessary in order to improve their quality of life.

Key words: HIV, OHIP-14, Decay-Missing-Fill index, oral health

CLINICAL AND EPIDEMIOLOGICAL CONSIDERATIONS IN ACUTE VIRAL HEPATITIS A IN 2014



MIHAELA CĂTĂLINA LUCA^{*,}, IRINA TEODORESCU^{*}, ELENA DUCA^{***}, ELISABETA BUZOI^{*}, IOANA ALEXA^{*}, A.ST. LUCA^{**}**

***Infectious Diseases Hospital "Sf. Parascheva" Iasi**

****University of Medicine and Pharmacy "Gr.T.Popa" Iasi**

*****Directorate of Public Health**

Globally, symptomatic HAV infections are believed to occur in around 1,5 millions of people a year. There is however likely tens of million of infections in all. Romania is a country with high prevalence of hepatitis A (anti HAV antibodies higher than 8%), but the incidence varies significantly among the regions. Thus, the district of Iasi was a region with high incidence of hepatitis A from 1995 until 2008 but the number of cases decreased progressively up to 4-9 cases/year in 2009 and remained at this level until 2014.

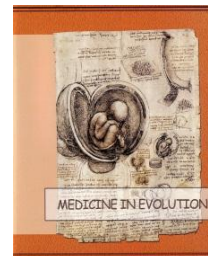Material and methods: This is a retrospective study on 284 cases of hepatitis A admitted in the Infectious Diseases Hospital of Iasi, between January- December 2014. Data were collected from patients records, epidemiological investigations and reports of infectious diseases specialists and primary care physicians. The diagnosis was based upon ALT and bilirubin values and presence of Ig M antiHAV antibodies in blood samples.

Results: Between January to December 2014, in the Infectious Diseases Hospital of Iasi were admitted 284 cases of A hepatitis, most of them (227 cases) being hospitalized from August to December. The incidence reached the peak value in October (66 cases) and November (96 cases). These reflect an outbreak, affected at least 167 people from 5 different areas. There were some sporadic cases too, with no apparent link with the people from affected areas. Patients were represented mostly by children of 5 to 9 year of age (51,5%). Poor sanitation, hygiene and overcrowding were the main causes of these outbreaks. Digestive symptoms were prevailing, associated, in few cases, with general symptoms such as asthenia (40,96%) and fever (17,62). Important cytolysis (> 1000 UI/ml) was present in 88.5% adults and 61% children population. Blood bilirubin had significantly high values (5-10 mg%) in adults population (85.7 %), while children had mostly anicteric forms of the disease. The prognosis was good in all cases, the symptoms improve after 6 to 10 days in 47% of cases, associated with slower normalization of transaminases.

Conclusion: Although the incidence of hepatitis A seems to decrease nationwide in the last few years, Iasi County is still a high endemicity region. Epidemiological pattern is represented mainly by small outbreaks in children population in relation with poor socioeconomic, hygienic and sanitary conditions.

Keywords: hepatitis A, outbreaks

TREATMENT IN CHRONIC C HEPATITIS- PAST, PRESENT AND FUTURE



MANUELA CURESCU, BIANCA CERBU

Clinic of Infectious Diseases, University of Medicine and Pharmacy "Victor Babes" Timisoara

Introduction: Chronic C hepatitis represents a global health problem, being five times more frequent than HIV infection. 170 millions of people are infected, that represents 3% of world population. In Romania, prevalence of the infection is 3,23%, that means 697680 persons infected, almost 99% being infected with genotype 1 HCV virus.

Material and methods: From 1989, the gold standard of treatment was represented by Interferon, with a Sustained Viral Response (SVR) of 6-16%. The addition of Ribavirine to the treatment raised the SVR to 35-43% and the combination of Pegylated Interferon + Ribavirine to 47-60%. The introduction of the first generation of Protease Inhibitors in 2012 (Boceprevir and Telaprevir) led to a SVR of 68-75%, among HCV treated patients. Today, in Romania in 2015 we treat the patients with the gold standard of the year 2003: Peginterferon + Ribavirine. Meanwhile, new molecules, protease inhibitors and polymerase inhibitors were approved: 2013 Sovaldi (Sofosbuvir), 2014 Olysio (Simeprevir), 2014 Harvoni (Ledipasvir + Sofosbuvir) and Daklinza (Daclatasvir). Beginning with January 2015, EMA approved all Interferon free regimen VIEKIRAX (ombitasvir / paritaprevir / ritonavir tablets) +

EXVIERA (dasabuvir tablets), 12 weeks, with a SVR rate of 99,6- 100% in genotype 1b infected patients.

Conclusions: Chronic C hepatitis is the first and only viral disease that can be cured. Are we still waiting?

TRUTH OR SECRET?

**DANIELA BIRIS, TEODORA MOISIL, VOICHITA-
ELENA LAZUREANU**



**Clinical Hospital for Infectious Diseases and Pulmonology "Victor Babes" Timisoara
University of Medicine and Pharmacy "Victor Babes" Timisoara**

HIV is one of the best well-guarded secrets of those who have it. HIV infection does not consist only in medical issues, but also psiho-emotional problems, patients need to face very difficult situations that imply a high level of emotional stress. Children who have been infected during the '86-'90s reached an age when they wish to start a family. Married life is characterised by love and harmony, in the same time it requires a certain level of commitment respect, care and support. Each partner has the responsibility to protect the health and integrity of his or her partner and children. For patients who are seropositive and whose children are seronegative there is a new challenge and that of sharing the diagnosis with them or keeping it a secret.

Therefore we have a very important question: "Do I tell the truth to my child or do I keep the secret?"

In order to answer this question 250 randomly chosen people answered a questionnaire: 23 seropositive couples, 41 serodiscordant couples, 72 seropositive patients and 50 qualified medical staff.

The results that have been obtained show an outstanding percentage of 79,2% of the questioned people do NOT want to reveal the truth while only 20,8% would be willing to say YES to the commitment of telling the truth.

Patients who are seropositive are influenced by the discrimination and the stigma that this virus has brought to them along the time and that is why they wish to keep the secret. The joy of having a seronegative child is unimaginable in this situation, therefore the reason why a parent would decide to hide such a secret from his/her own child is to protect him/her. From a psychological point of view it is not recommended to give advice, but to give arguments pro and cons in this way the patient being able to make the best decision for him/her, a decision they will be responsible for.

Keywords: seropositive, couple, seronegative child, truth, secret

EVOLUTION OF VACCINES AND THEIR EFFECTIVENESS, FROM THE FIRST ATTEMPTS UNTIL TODAY, ARAD COUNTY EXPERIENCE



DANA NEGRU*, VICTOR TOMA**, IOANA JURCĂ**, GHEORGHE NINI**, LILIANA BRAN**, MARIANA NAGY***

*Public Health Department, Arad

**West University "Vasile Goldiș", Arad

***University "Aurel Vlaicu" Arad

Introduction. The goal of preventive measures in infectious diseases is interrupting transmission of germs. Measures can be nonspecific, where the patient is isolated, and specific, by passive and active immunization and chemoprophylaxis.

Material and methods. All preventable infectious diseases recorded in Arad County were analyzed, data being statistically processed with SPSS 17.0 for Windows and MedCalc. Were followed rejection and missing rate of vaccination, temporary contraindication, omissions, lack of vaccines and adverse reactions to vaccination. In assessing vaccination coverage estimates we took into account the absence of BCG and MMR doses, 3 doses of HepB, 4 doses of DTPa, Hib, IPV to 1 year old.

Results. Média for vaccine coverage in the last 2 years does not exceed 85% for diphtheria, tetanus, whooping cough, Haemophilus influenza type B and polio and for flu was 19%. Flu vaccine were available for 22.82% of the required doses. There were recorded tuberculosis and hepatitis B cases, although yearly vaccination coverage exceeding 90%. Cases of incompletely vaccinated reach a rate of 20%. Rejection and missing rate of vaccination are responsible for 46% of cases in non-vaccination. Notable side effects were recorded only for TB, dT and flu vaccine, with medium and mild severity.

Conclusions. Vaccine-preventable diseases have declined considerably infectious disease morbidity. In assessing rejection of vaccination, the physician and parent must consider the risk by disease and vaccination versus benefit of vaccination. Option for the vaccination should be vigorous for tetanus, polio, diphtheria, viral B hepatitis and whooping cough.

Key words: vaccination, rejection, benefit

VALUES OF BACTERIOLOGICAL INVESTIGATION IN URINARY TRACT INFECTIONS AT INFANTS



DANIELA T. MARȚI*, RUJIȚA CIUREA**,***, L.NEGRUȚIU*,
SIMONA TALPEȘ***

*Discipline of Microbiology, UVVG, Arad

**Discipline of Farmacology, UVVG, Arad

***County Hospital of Arad

Objectives: Uroculture values in etiologic diagnosis and treatment of urinary tract infections (UTI) at infants and atypical symptoms pointing to this category of patients is a topical issue in their pathology.

Material and methods: We have tracked retrospectively 40 infants hospitalized in the Pediatric Clinic 1 of the Arad County Hospital with other clinical diagnosis on admission than urinary infection. We have identified microbial germs out of all the 40 positive urine samples. Etiological identification was made by classical methods and also using API kits. The antibiogram was performed by the diffusion method.

Results: We have identified signs and symptoms present on admission and the others detected along the way, the most common being fever (70% of cases), somnolence (25% of cases). Among the favorable factors are: poor hygiene (45% of cases), phimosis (27.5% of cases). Bacteria detected in urine cultures are: E. coli (35% cases), Klebsiella pneumoniae (17.5% cases).

Conclusions: We had noticed a correlation between the favorable factors and UTI incidence in infants hospitalized with nonspecific clinical manifestations. The need to perform urocultures is essential for infants with febrile syndrome.

Key words: infant, uroculture, fever

IMPLICATIONS OF THE ROTAVIRUSES IN ACUTE DIARRHEA



RUXANDRA LAZA*, ALEXANDRU CRIȘAN*, NARCISA NICOLESCU*, ADELINA MARINESCU, LUCI ROTAR****

***CI II Infectious Diseases, University of Medicine and Farmacy “Victor Babes” Timisoara**

****“Victor Babes” Infectious Diseases and Pneumoftiziog Hospital Timișoara**

Introduction: Diarrhea represents a major public health problem, due to the diversity of etiologic agents, the intensity and the gravity of clinical manifestations, the endemoepidemic extensive disposition of the disease. The etiology of infectious diarrhea is very diverse, implying numerous pathogenic germs of bacterial, viral, parasitical, mycotic origin. The Rotavirus infection (RV) represents the most important cause of hospitalization for gastro-enteritis suffering children.

Material and method: The work includes a retrospective study, made on 120 patients admitted at Clinic II of “Victor Babes” Infectious Diseases and Pneumoftiziog Hospital Timișoara, diagnosed with Enterocolitis with Rotavirus, during april 2014 – april 2015.

Objectives: The analysis has been focused on the following aspects: the age groups structure of the cases, the place of the disease’s outburst (hospital or familiar environment), subjective and objective symptomatology, the necessity of parental rebalancing, information regarding the progress of the disease.

Discussions: There has been identified a raised prevalence at the male gender, the period from the debut of symptomatology until the admittance has been, on average, of 48 hours. Of the total number of patients, 55% could be considered to have nosocomial infections. The average time of hospitalization has been of 5 days. The evolution has been favourable in all cases.

Conclusions: Nosocomial infections constitute one of the major causes of morbidity amongst admitted patients. In this pathology, the implication of Rotaviruses is of great importance and extremely topical.

Keywords: Rotavirus infection, Acute Diarrhea, nosocomial infection

FECAL MICROBIOTA TRANSPLANTATION IN CHILDREN WITH RECURRENT CLOSTRIDIUM DIFFICILE INFECTION



GHEORGHE JUGULETE

Medic Primar Boli Infecțioase, Sef Secția Clinică IX, Boli Infecțioase – Pediatrie
Institutul Național de Boli Infecțioase "Prof. Dr. Matei Bals"
Sef de Lucrări U.M.F. "Carol Davila", București

Background: Clostridium difficile is a ubiquitous bacteria frequently found in the human saprophytic intestinal flora. Rarely, it is involved in the etiology of acute intestinal infections, especially in the circumstances of dysmicrobism or host immunodeficiency.

Material and method: We present two severe recurrent cases of Clostridium difficile colitis in children admitted in The National Institute of Infectious Diseases "Prof. Dr. Matei Bals". In both cases, diagnosis was established through culture and PCR. Treatment was administered according to standard protocol, with initial favorable evolution but with relapses occurring at increasingly shorter intervals. The first case is a 7 year old girl with 4 relapses over 18 months, and the second case is a 5 year old boy with 6 relapses in 24 months.

In this situation we have opted for fecal transplantation, donors being the mother in the first case and the father in the latter.

Results

Recolonization was achieved through a nasogastric tube inserted up to the proximal segment of the duodenum. The procedures took place without incidents. The first case has not registered any relapses 12 months after transplantation, nor did the second after 4 months.

Conclusions

Fecal microbiota transplantation is a rarely used therapy, this being the first time the procedure was used in a child with recurrent C. difficile infection.

We consider that the intestinal recolonization with bacterial flora from a healthy donor was a success, the child being regarded as cured.

These cases are a medical premiere for Romania, worldwide being few cases performed and reported.

CHARACTERISTICS OF THE 2014-2015 INFLUENZA SEASON IN THE INFECTIOUS DISEASES HOSPITAL OF IASI



ANDREI VÂȚĂ*, IOANA ALINA ALEXA**, ELENA DUCA***,
FLORIN ROȘU**, CĂȚĂLINA MIHAELA LUCA*

*University of Medicine and Pharmacy "Grigore T. Popa" Iași

**Infectious Diseases Hospital Iași

***Public Health Department of Iași

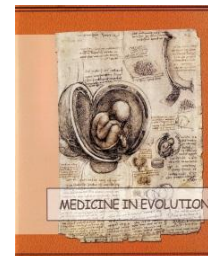Despite national and international vaccination programs, influenza still raises significant health and social problems due to its frequency and severity. We propose analyzing the particularities of the flu cases in Iași Infectious Diseases Hospital in the 2014-2015 season.

Material and Methods: retrospective study of influenza cases diagnosed (clinically and/or laboratory-confirmed, in children and adults) in the Infectious Diseases Hospital of Iași between 10/15/14 to 04/15/15. From their medical records, demographic, epidemiological, clinical, laboratory and therapeutic data were extracted. Confirmation of the diagnosis was made by identifying the influenza virus with RT-PCR from a throat / nasal specimen within the Cantacuzino Institute Bucharest.

Results: The first case occurred in early January 2015 and was followed by another 85. The maximum number of cases was recorded in March - 45.3%. Hospitalized patients were adults 93%, females 55.8%, from urban areas 56.9%. More than half of them (53.4%) of them had significant co-morbidities. The onset of disease was acute in 82.5% of cases. The patients were hospitalized an average after 3.4 days of illness. The most common symptoms were fever (over 38°C) - 87.2%, cough - 82.6%, myalgia and arthralgia - 48.8%, headache - 43%, dyspnea - 33.7%, marked fatigue - 27.9%. Other observed symptoms were chest pain - 23.3%, vomiting - 12.8%, sore throat - 11.6%, dysphonia - 3.5%. The mean maximum temperature during hospitalization was of 38.9°C. 54.6% of cases had severe disease who required oxygen therapy and in 13.9% ICU hospitalization (for a mean of 4.5 days). 55.8% of cases were laboratory confirmed - 22 influenza A H1, 18 A H3 and 8 Type B. The mean WBC on admission was 7402.2 /mm³, with an average of 65.3% PMN. 20.9% of patients had thrombocytopenia; VSH was on average 24.5 mm/h, and fibrinogen 3.7 g/l. Chest radiograph was normal in 51.9% of cases, showed interstitial opacities in 29.9% and of alveolar type in 18.2%. Oseltamivir treatment was used in 66.2% of patients. Five deaths were recorded (lethality - 5.81%).

Conclusions: The 2014-2015 influenza season had a slightly delayed onset, involved viral subtypes contained in the usually used vaccine, which frequently generated severe illness, sometimes fatal, particularly in patients with other associated co-morbidities.

PREDICTION MODEL FOR CHRONIC KIDNEY DISEASE IN HIV PATIENTS



GABRIELA-CORNELIA HOROSANU

University of Medicine and Pharmacy “Carol Davila” Bucharest

Background: HIV associated nephropathy due to glomerular nephritis is a known parenchymal disease and the issue has been studied in correlation with the impact of the antiretroviral therapy (ART). Nevertheless, the sum of risk factors involved in the causes and evolution of CKD is much broader and slight shifts to atherosclerosis-based CKD had been seen to occur in patients lately, due to their improved lifespan, to the improved therapy, and also because of a different set of risk factors. Therefore, in any prediction of CKD occurrence or kidney disease evolution, contributing factors such as diabetes, hyper blood pressure, HCV or perturbing lifestyle factors have to be addressed.

Objectives: Because HIV patients currently live more with the disease and are experiencing several therapeutically schemes during their lifetime, the occurrence of CKD in these patients increases. In order to improve their life condition and to decrease the disease occurrence or to slow down its evolution when occurred, prediction models have to be developed. The current study proposes a CKD risk stratification and uses different mathematical models to optimize the function that will determine the incidence for a specific cohort, with initially known parameters. The approach of the current study is theoretical, having as main objective the development of different models that will be furthermore validated on the Romanian cohort of HIV patients.

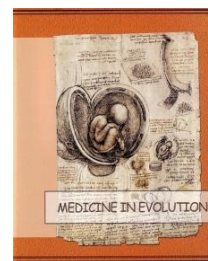Material and methods: The CKD risk stratification includes 5 risk types of factors: individual (age, gender, BMI), HIV-related factors (CD4 count, viral load, HCV), therapy-related, circulatory (co-morbidities, such as diabetes, HTA, MVD), genetic (APO-L1 and MyH9 polymorphisms), and behavioral (smoking, alcohol consumption, drug abuse). A multinomial regression model is used in order to generalise the correlation equations and to develop the mathematical framework, including the limit conditions of the renal function, for the prediction models. In all the prediction models proposed there are two dependent variables, which determine the trend of the curve (Wilcoxon test and linear regression): serum creatinine and eGFR, evaluated with the CKD-EPI equation.

Results and Conclusions: Simulations of the 5 types of risk factors have been overlapped on the same risk graph, in order to highlight the additional impact. The risk degree of each factor is previously calculated using differential equations to predict its impact for a specific period of time and a multivariate analysis was furthermore conducted using Cox model. A preliminary validation is presented, but the study will continue with a robust validation of the proposed models and an evaluation of their predictive ability. The identified renal risk scores will be of outmost use in clinical practice, in order to estimate with accuracy the evolution of each patient.

Keywords: risk models, occurrence prediction, CKD, HIV patients

Acknowledgement This paper is partially supported by the Sectoral Operational Programme Human Resources Development (SOP HRD), financed from the European Social Fund and by the Romanian Government under the contract number POSDRU/159/1.5/S/137390.

THE PSYCHOLOGICAL APPROACH – ESSENTIAL ASPECT OF THE PATIENT MANAGEMENT IN HIV/AIDS - CASE REPORT



**LARGU MARIA ALEXANDRA*, LEBĂDĂ A., PRISĂCARIU L.,
NICOLAU CRISTINA, MANCIUC DOINA CARMEN***

Infectious Diseases Clinical Hospital Iași

***University of Medicine and Pharmacy „Gr. T. Popa” Iași**

Objectives: Highlighting the importance of the psychological support and counseling for managing the HIV-positive patient, from the time of diagnosis throughout the patient's life.

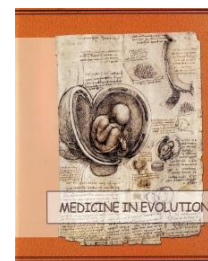Material and methods: We analyzed one patient's medical file, from the time of positive diagnosis until present time. We corroborated the information with the data from the psychological records in the psycho-social service.

Results: L.M, male, 26 years old, from a rural area, admitted in 10 August 2014 for a febrile syndrome and diarrhea, and severe lose of weight. The biological aspects are: hemoglobin 11,1 g/mmc, white blood cells 6170/mmc, PMN 70%, VSH 60 mm/h, total proteins 62 g/mmc. The pulmonary X-Ray revealed micronodular opacities in both lung fields; tongue scrape revealed candida. The psychological interview revealed repeated unprotected sexual intercourse with a HIV-positive woman. CD4 – 26 cells/mmc, VL 1.660.000 copies/mmc. The patient required extensive counseling after the HIV diagnosis, due to severe the emotional impact on himself and his extended family (wife, children, mother in-law). Psychological counseling aimed to reduce the patient's anxiety and suicidal ideation, in order to assure the psycho-emotional balance required for adherence to ART. It also targeted the patient's family, focusing on accepting the patient and the diagnosis. The long term effect of psychological counseling reflected on the improvement of the patient's medical condition, gaining up to 25 kg in march 2015, with undetectable VL and a CD4 cell count of over 400/mmc.

Conclusions: Repeated psychological counseling sessions and psychological support for both the patient and his family are as important as medical management for adherence to antiretroviral therapy.

Keywords: HIV/AIDS, psychological counseling, adherence to ART.

CLINICAL, IMMUNOLOGICAL AND VIROLOGICAL PROFILE OF PATIENTS NEWLY DIAGNOSED WITH HIV INFECTION IN A YEAR OF REFERENCE



SIMONA ERSCOIU*, I. C. POPA, OLIVIA BURCOS**, GRATIELA TARDEI**, MARIA NICA*, E.CEAUSU***

*** University of Medicine and Pharmacy "Carol Davila" Bucharest**

****Clinical Hospital for Infectious and Tropical Diseases Dr.V.Babes, Bucharest**

Background. Clinical manifestations of HIV infection are extremely complex depending on the affected organs and the prevalence of concurrent infections related to geographic area. The initial clinical presentation may imitate the symptoms of common endemic diseases, but may also depend on the route of HIV acquisition. Last decade, in Romania, the major route of HIV transmission was heterosexual and TB was the most common opportunistic infection, both screening and evolution. With increasing numbers of iv drug users (IVDUs), parenterally route of transmission become dominant, especially in Bucharest. Year 2013 became the year with most cases of IVDUs, newly HIV diagnosed.

Aims. Evaluation of clinical manifestations and signs, immunological and virological aspects and subsequent evolution of patients newly diagnosed with HIV infection, in 2013 (year of occurrence in a large number of parenteral route of HIV transmission, the way of iv drugs) in a clinical infectious diseases unit.

Methods. Retrospective study of 187 new HIV infected cases diagnosed in 2013, in HIV/AIDS. Casa Andreea Department, Clinical Hospital of Infectious and Tropical Diseases Dr V. Babes, Bucharest. HIV diagnosis was based on history, member in a risk group, clinical manifestations, immunological and virological investigations.

Results. In 2013, 187 new cases of HIV infection were detected. Males as urban origin were dominant (74%). The median age was 32 years, 10% of those were social cases. The two main routes of HIV transmission were identified: parenteral route in 63% of IVDUs and 21% sexual way. Route of transmission could not be defined in 14% of patients. At screening, 44% of new cases were classified in asymptomatic phase of HIV infection, many of them being IVDUs (66%). The number of CD4 + lymphocytes correlated with the clinical status of patients. Those who were in stage AIDS had 51 lymphocytes / mmc median value of CD4 –IVDUs and 28 lymphocytes / mmc in SX. "Late presenters" of HIV infection were 21 patients (14 IVDUs) and 46 cases were classified as "very late presenters" (29 IVDUs). Wasting syndrome was diagnosed in 67% of IVDUs and 33% of SX. At least, one opportunistic infection (O.I.) experienced 67% of patients. OI were represented by cerebral toxoplasmosis (6 cases), PCP (5 cases), and one case of criptococcosis, CMV infection, PML, invasive cervical cancer, all in SX. Antiretroviral therapy was initiated in 33% of patients (26% IVDUs and 46% SX), of which almost a quarter, in first ten days of confirmation of HIV infection. Most of patients received triple therapy: 2 NRTI and an NNRTI.

Mortality was 17% by the time of this study, most deaths being caused by MDR TB (68% IVDUs and 32% SX).

Conclusions. 2013 represents the year with most new detected adult cases with HIV infection, in our clinic and the year where parenteral route brings us in actuality world. TB infection in both major categories represents the most frequent serious OI. CNS infections were the most severe OI at SX.

Keyword: HIV infection, manifestations at the diagnostic moment

DIAGNOSTIC AND THERAPEUTIC CHALLENGES IN THE MANAGEMENT OF MUCORMYCOSIS: PRESENTATION OF TWO CLINICAL CASES



VALERIU GHEORGHITA^{*,***}, RAZVAN HAINAROSIE^{**,*****},
ALINA ELENA BARBU^{***}, RAZVAN VASILESCU^{****}, ELIZA
GRAMADA^{*****}, CLAUDIU SOCOLIUC^{*****}, MONA POPOIU^{***},
RUXANDRA MOROTI^{***,*****}, FLORIN ALEXANDRU
CARUNTU^{***,*****}

^{*}Carol Davila Central Universitary Emergency Military Hospital

^{**}2Hociota ENT Institute

^{***}Matei Bals National Institute for Infectious Diseases

^{****}Colentina Clinical Hospital, Department of Diabetes, Nutritional and Metabolic Diseases

^{*****}Colentina Clinical Hospital, Department of Pathology

^{*****} University of Medicine and Pharmacy "Carol Davila" Bucharest

Background: Mucormycosis (MCM) is a life-threatening invasive fungal infection caused by fungi belonging to the Mucorales order. It is reported as a rare disease, which likely explains the late diagnosis and perhaps poor prognosis despite aggressive treatment.

Considering that Amphotericin B (AMB) treatment is rarely available in our country, the objectives of the presentation are addressed underlining the diagnosis and treatment characteristic of MCM in these settings.

Material and methods: We report two clinical cases of MCM hospitalized in Matei Bals National Institute for Infectious Diseases. The first case, is about 56-years-old male patient with poorly controlled diabetes and hypertension, who was diagnosed in August 2014 with nasopharyngeal MCM by histopathological exam and culture. The second case, a 70-years-old male patient with alcoholic decompensated cirrhosis and diabetes, was admitted in our clinic in March 2015 with diagnosis of rhino-orbital MCM. The brain MRI confirmed the left cerebral frontal lobe extension of the MCM. In each case, Mucor species was confirmed from the tissue specimen culture. In the first case, Mucor was identified as Rhizopus oryzae by molecular methods. Antifungal susceptibility testing confirmed the susceptibility to Posaconazole (POS).

Results: In the first case, the antifungal regimen containing lipid formulation of AMB plus POS (800 mg/day) for 11 days, followed by POS (1200 mg/day) for another 38 days, in addition to extensive surgery, led to complete resolution of the disease. In the second case, the clinical status of the patient was severely deteriorated during treatment with POS (800 mg/day) making surgical resection worthless. He was discharged home after 11 days, at family request.

In conclusion, prompt initiation of treatment with POS in addition to surgical debridement seems to be an efficient strategy, whenever AMB treatment is not available. However, the individual prognosis of MCM is mainly driven by early diagnosis, underlying disease and treatment strategy.

Acknowledgment: This work received financial support through the project entitled "CERO-career profile: Romanian Researcher", grant number POSDRU/159/1.5/S/135760, cofinanced by the European Social Fund for Sectorial Operational Programme Human Resources Development 2007-2013.

Key words: nasopharyngeal and rhino-cerebral mucormycosis, posaconazole, Rhizopus oryzae

BILIODIGESTIVE FISTULA – RARE CAUSE FOR PROLONGED FEVER SYNDROME. CLINICAL CASE PRESENTATION



ALEXANDRU CRIȘAN*, LUCI ROTAR**, ADELINA MARINESCU**, NARCISA NICOLESCU*, RUXANDRA LAZA*

* CI II Infectious Diseases, University of Medicine and Pharmacy “Victor Babeș” Timișoara

**“Victor Babeș” Infectious Diseases and Pneumoftiziog Hospital Timișoara

Background: Mucormycosis (MCM) is a life-threatening invasive fungal infection caused by fungi belonging to the Introduction: In the deciphering of the prolonged fever syndrome, a careful diagnosis argument, accompanied by a proper selection of the biological and paraclinical means, allowed the determination of the diagnosis of biliodigestive fistula before the emergence of its usual, life-threatening complications (peritonitis, intestinal occlusion).

Material and method: The clinical case about to be exposed illustrates the particular evolution of a biliodigestive fistula, whose development has had for clinical expression only the presence of some nonspecific symptoms: 3-4 weeks evolutioning fever, chills, pain in the right hypochondrium.

Discussions: The diagnosis of biliodigestive fistula has been significantly based on the ultrasound and CT exams' data, later on confirmed intraoperatively.

Conclusions: An anamnestic, objective and well-conducted examination, accompanied by a careful sequence and selection of the biological and paraclinical investigation, allowed the formulation of a diagnosis that belongs to great surgical emergencies, even in the case of oligosymptomatic evolution.

Keywords: Biliodigestive Fistula, Prolonged Fever Syndrome

SEVERE ACUTE LIVER FAILURE IN A PATIENT WITH LIVER CIRRHOSIS HBV AND HDV



BIANCA CERBU, MANUELA CURESCU, DOGARU DELIA, IOSIF MARINCU

*

Department of Infectious Diseases, Pulmonary, Epidemiology and Parasitology, University of Medicine and Pharmacy "Victor Babes" Timisoara

Objective: Presentation of a clinical case with cirrhosis VHB+VHD and acute liver failure detected after the appearance of the icteric syndrome (sclero jaundice skin).

Patients and methods: The authors present the case of a 25 years old patient, known with chronic HBV infection for 11 years, with HBV DNA below 51 copies per milliliter. The patient comes from urban areas, Galati city. The patient is admitted in the Infectious diseases clinic Timisoara, by county emergency service with suspicion of acute viral hepatitis. The disease onset was approximately 10 days ago, with intense jaundice scleral skin, marked asthenia, itching and dark urine. Clinical examination on admission: general state moderately influenced, intense jaundice scleral skin, subcutaneous tissue weak represented, soft abdomen, mobile with breathing, slightly painful on palpation, acolic stool approximately 4 in a day, palpable spleen 1 centimeter below left costal rebord, dark urine, without any other changes.

Results: in chronological order- abdominal ultrasound: small liver, granular, micronodular, splenomegaly 14,8 centimeters, marked venous dilatation in the splenic hilum. Transient elastography [FibroScan examination] 35,3 kPa. Blood tests (Biology): Tr=89.000 μ L, TGP=1307,9 U/L, TGO=1781,9 U/L, BD=19,45 U/L, BT=21.69 U/L, GGT=193.4 U/L, cholinesterase=2968 U/L, PT=54,4%, INR=1.49, AgHBs -reactiv, IgM HBc-non reactiv, AcDelta- reactiv performed for the first time. Antibiotic treatment was started, hepatoprotectors corticosteroids therapy, diuretics, rebalancing hydro electrolytic solutions, hemostatic therapy, amino acid therapy. The patient has initially a favorable evolution with clinical remission of the jaundice syndrome and remission of the hepatocytolysis, unfavorable later with a marked increase in biliary retention syndrome, and constant low cholinesterase, add the ascites. At this stage, it is decided the transfer to Fundeni Hospital in Bucharest for liver transplantation.

Conclusion: Wrong or incomplete diagnosis of chronic infection with the virus B may contribute to the evolving unfavorably a patients.

DISEMINATED CRYPTOCOCCOSIS IN A HIV LATE PRESENTER PATIENT



OVIDIU ROSCA*, ANDREEA ARDELEANU**, MONICA CIALMA*,
DANIELA MIHALCEA**, VALERIA BICA, CAMELIA NIȚĂ, IOSIF
MARINCU*

*Department of Infectious Diseases I, University of Medicine and Pharmacy “Victor Babes” Timisoara

**Department of Infectious Diseases I, Clinical Hospital of Infectious Diseases and Pneumophthisiology “V. Babes” Timisoara

Background: Cryptococcal infection or cryptococcosis is caused by infection with Cryptococcus neoformans that is present in soil contaminated with pigeon excreta and it is distributed all over the world. The organism enters the body through respiratory tract and dissemination is haematogenous to CNS, skin, bone, lymph node, kidney, liver, spleen and other viscerae. Cryptococcal meningitis and disseminated cryptococcosis is a common and severe opportunistic infection in advanced HIV disease. It is invariably fatal if left untreated, and carries a high mortality even with treatment.

Objectives: To present a case of disseminated cryptococcosis in a patient with advanced HIV.

Patients and methods: We report the case of a patient diagnosed with HIV Infection in June 2014. At that time the patient was severely immunocompromised (CD4=17 cells/ μ l, HIV- ARN=191.547 copies/ml) and presented persistent fever, oral and esophageal candidiasis, generalised pustulosis and wasting syndrome. The imaging evaluation (abdominal echography and CT) shown multiple splenic abscesses. Under conservative treatment the evolution was unfavorable, so splenectomy was performed. The splenic tissue cultures revealed Cryptococcus Neoformans and Acinetobacter Baumannii and the CSF direct examination and cultures were also positive for Cryptococcus Neoformans.

Results: Despite the administration of antifungal, antibiotics and antiretroviral treatment the evolution was unfavorable leading to the death of our patient.

Conclusions: The clinical presentation of disseminated cryptococcosis is variable and depends on the organ and systems involved. Although the most common form of the disease is meningitis, dissemination to extraneural sites can be seen and they usually carry grave prognosis. In patients with compromised immunity, the prognosis is worse. Even with optimum treatment rate the mortality remains high. In resource poor setting, treatment options remain very limited which further add to the failures in treating these patients.

THYROID DYSFUNCTION IN SEPSIS: CORRELATION WITH SEVERITY AND FINAL OUTCOME IN A PROSPECTIVE STUDY



VALERIU GHEORGHITA^{*,}, ALINA ELENA BARBU^{**}, MONICA LIVIA GHEORGHIU^{***,****}, FLORIN ALEXANDRU CARUNTU^{**,****}, ADRIAN STREINU-CERCEL^{**,****}, RUXANDRA MOROTI^{**,****}**

***Carol Davila Central University Emergency Military Hospital**

****Matei Bals National Institute for Infectious Diseases**

*****Parhon National Institute of Endocrinology**

****** University of Medicine and Pharmacy "Carol Davila" Bucharest**

Background: Critical illness, such as sepsis, is often associated with thyroid hormone abnormalities, as part of an adaptive metabolic response in an attempt to increase resistance to different stressors by lowering the cellular metabolic activity.

The objective of our study was to evaluate the thyroid function during sepsis in order to identify a possible correlation with severity and final outcome of sepsis in a prospective on-going study.

Material and methods: We designed a prospective, non-interventional cohort study conducted in Matei Bals National Institute for Infectious Diseases, over a period of six months (January to June 2015). Our main inclusion criteria were sepsis caused by bacterial infection (systemic inflammatory response syndrome plus at least one of positive blood culture or procalcitonin value over 10 ng/ml) in HIV negative adult patients who gave their written informed consent. Apart from demographics, clinical and microbiological data we measured serum thyroid hormones (TSH and fT4) and procalcitonin (PCT) at four different time: T0 (admission), T1 (24 hours), T2 (72 hours) and T3 (the seventh day).

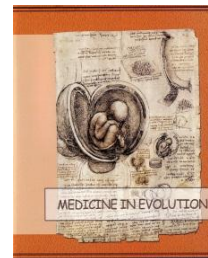Results: We enrolled 27 patients who met the inclusion criteria. The median age was 67 years, (IQR, 57-78) and 55.5% (n=15) were male. According to severity of sepsis at baseline, 40.7% (n=11) of patients had severe sepsis and 18.5% (n=5) septic shock. The median value of PCT at diagnosis was 48.8 ng/mL, (IQR, 10.7-88.04). In 48.1% (n=13) of patients we were able to find the etiology, the gram negative bacilli being the most frequent isolates (84.6%, n=11). The in-hospital mortality was 18.5% (n=5). Thyroid dysfunction was present at 29.6% (n=8) of patients, 62.5% (n=5) having hypothyroidism. The median value of TSH in patients with hypothyroidism was 5.134 UI/mL, (IQR, 4.224-6.137), greater than 1.81 UI/mL, (IQR, 1.183-2.975) in euthyroid patients, p=0.27. None of these patients had been known with thyroid dysfunction. 75% (n=6) of patients with thyroid dysfunction had more severe disease at baseline. The mortality was 37.5% (n=3) in patients with thyroid dysfunction compared to 18.5% (n=5) in the whole cohort, p=0.32.

Conclusion: Thyroid dysfunction was diagnosed in about quarter of patients with sepsis and seems to correlate with the severity of sepsis and poor prognosis in clinical practice, although our analysis did not reach statistical significance.

Key words: sepsis, thyroid dysfunction, endocrine dysfunction, severity and outcome in sepsis

Acknowledgment: This work received financial support through the project entitled "CERO-career profile: Romanian Researcher", grant number POSDRU/159/1.5/S/135760, cofinanced by the European Social Fund for Sectorial Operational Programme Human Resources Development 2007-2013.

ANTI-MEASLES VACCINATION – PRO AND AGAINST



NARCISA NICOLESCU*, ALEXANDRU CRIȘAN*, EMILIA NICOARĂ*, VOICHIȚA LĂZUREANU*, RUXANDRA LAZA*, VIRGIL MUSTA*, ADELINA MARINESCU**

***CI II Infectious Diseases, University of Medicine and Pharmacy “Victor Babeș” Timișoara**

****“Victor Babeș” Infectious Diseases and Pneumoftiziog Hospital Timișoara**

Introduction:

It is well known the fact that measles (also known as morbilli) is an infectious-contagious disease, viral, endemoepidemic disease that can generate respiratory, ORL-related and neurological complications. It is a disease preventable by vaccination.

Objectives:

The analysis of the incidence of measles in Timiș county in the last years.

Comparison with other European countries' situation, as well as with the USA.

The efficiency of the vaccination programs.

Pro and against arguments regarding anti-measles vaccination.

Material and methods:

We have made a retrospective study regarding measles' incidence in Clinic II Infectious Diseases of the Victor Babeș Hospital Timișoara during 2008-2014, compared to the situation in 1993, respectively 2004-2005 – age groups affected, complications, lethality.

Results and conclusions

In 1993 prevailed pulmonary and neurological complications, respectively encephalitis, some with unfavourable evolution, resulting in high lethality rates.

During 2004-2005 there have been 309 cases in Timiș county with 219 admissions, mostly respiratory complications, small lethality rates.

There have been years – 2008, 2009, respectively 2013-2014 – with no measles cases in Timiș county.

In 2011/2012 has been registered an epidemic apex with 272, respectively 231 cases with especially pulmonary and ORL-related complications.

Measles continues to represent a problem, epidemic outbursts can emerge anytime: most recently, the USA example with over 100 declared cases.

Measles can be prevented by following the vaccination programs.

Keywords: anti-measles vaccination, measles' incidence.

CLINICAL AND EPIDEMIOLOGICAL ASPECTS OF INFLUENZA IN CHILDREN HOSPITALIZED BETWEEN NOVEMBER 2014 – MARS 2015 IN THE CLINICAL HOSPITAL OF INFECTIOUS DISEASES OF CONSTANTA COUNTY



SIMONA CLAUDIA CAMBREA*, ANA-MARIA-IANCU*,**,
SORINA CARP*, MARIA MARGARETA ILIE***

***Facultatea de Medicina si Farmacie, Universitatea "Ovidius" Constanta**

****Spitalul Clinic de Boli Infectioase Constanta**

Objectives: The annual surveillance of influenza cases is very important to identify circulating influenza virus strains. It is also performed in order to inform about the severity, impact and timing of seasonal epidemics, and to detect any emerging influenza viruses.

Material and methods: It is a retrospective study, based on the data obtained from the observation papers of hospitalized children in our clinic during the cold season 2014/ 2015. The specimens used were nasopharyngeal swabs and the detection of influenza virus was made by using nucleic acid amplification tests (RT-PCR).

Results: We noticed that from the 210 nasopharyngeal swabs collected from the children between 2 months and 14 years of age, 130 results were positive. From those, 7 cases were nosocomial infection. All cases occurred in unvaccinated children. Influenza A was diagnosed in 33 cases, 10 cases being with subtype H1N1 and influenza B was diagnosed in 97 cases. 43% of cases occurred in children of preschool age (≤ 6 years of age). Most cases occurred in February, representing 45.3% from all cases. The onset was with respiratory symptoms in 36.9% of cases, with digestive and respiratory complaints in 25.3% of cases and with myalgia and respiratory symptoms in 26.9% of cases. The main complications were pneumonia, meningismus and myositis.

Conclusions: According to the data from literature, in the last cold season, influenza B was predominated in children. It generally causes milder disease than type A, so no SARI was diagnosed in children. Influenza represents a significant public health threat, so it is important to perform vaccination in all groups of population including children.

Keywords: influenza, influenza virus subtype, nasopharyngeal swab, RT-PCR, public health.

SURVEILLANCE OF THE HIV PERINATALLY EXPOSED CHILD IN ROMANIA



MARIANA MARDARESCU, ADRIAN STREINU-CERCEL,
CRISTINA PETRE, MARIETA IANCU, SANDA VINTILA, DANIELA
VITELARU, CLAUDIU SCHIOPU

Compartment for Monitoring and Evaluation of HIV/AIDS Data in Romania, National Institute for Infectious Diseases "Prof. Dr. Matei Bals"

The recent years' experience has made us face a new typology of HIV cases- the outbreak within the numbers of people who inject drugs, as well as the necessity to adapt specific cares to the needs of the patients coming from the 1987-1990 cohort.

The latter present a complex pathology: they are therapeutically multi experienced, have adherence and resistance to ART problems and experience advanced stages of disease. Furthermore, most of them have reached a fertile age giving birth to their own children, for who the medical community must deliver a new approach.

The National Registry of pregnant women- infected with HIV and of perinatally exposed children represents an operational tool that collects data on the item „mother-child”, whose main role is to clearly display a national overview on the phenomenon of mother to child transmission.

The registry sides with a study launched at 1 January 2014 that focuses on pregnant women and HIV exposed children from all the regions in Romania. Additionally, the Registry will be linked with the National HIV/AIDS Data Base from the National Institute for Infectious Diseases “Prof. Dr. Matei Bals”, constituting another surveillance system of HIV/AIDS phenomenon in Romania.

In this context, the National Registry of pregnant women-infected with HIV and of perinatally exposed children provides an overall image on mother to child transmission of HIV phenomenon in our country. The Register stores personal data on: mothers and children, the child's medical history (physiological and pathology data), initial investigation, investigation at 6 and 18 months of surveillance; the mothers' personal data (time of HIV diagnosis, risk factors, disease and therapeutic history, peripartum immunological and virological investigation, information about the father and siblings).

*During 1 January 2013-30 March 2015, we registered 381 children with perinatal exposure to HIV, **32%** from newly diagnosed mothers, **36%** from the Romanian Cohort, **32%** from mothers known to have sexually acquired HIV.*

***75%** of women undertook ante-partum and intra-partum treatment while **23%** were diagnosed late and presented no prophylaxis or treatment by the time of diagnosis. **96%** of children perinatally exposed to HIV benefited from post partum prophylaxis.*

*From the total number of assessed children, **3.93%** were considered to be infected with HIV, with detectable viral load ever since their birth. Other evaluations emphasized the risks of ante-partum exposure in children, namely 19% exposure through the mothers' drug use, **16%** exposure to HCV and **22%** exposure to HBV.*

So far, evaluations were performed on several risk factors: postpartum ART, type of feeding, Type of birth, ART in pregnancy. The highest impact factor for the final assessment of children: postpartum ART prophylaxis ($p=0.004$). OR (odds ratio) for ART postpartum prophylaxis=2.286 and ART in pregnancy $p=0.001$. OR=2.273.

Statistical data reveal a slightly increased number of HIV infections in Romania.

The distribution of HIV/AIDS cases among PLWHA, by age groups (PLWHA 1985-2015) highlights that the largest number of infections impacts the infected population, now in their fertile age.

An important share in women in their fertile age belongs to the 1987-1990s cohort: and present several characteristics: long term survivors; associated complex pathology; advanced stages of diseases; therapeutic background, complex resistance mutations.

TREATMENT OF HIV-TB CO-INFECTION: AN OVERVIEW

CRISTIANA OPREA



“Victor Babes” Clinical Hospital for Infectious and Tropical Diseases Bucharest

The overlap between the human immunodeficiency virus (HIV) and tuberculosis (TB) epidemics has led to a dramatic upsurge in TB incidence, resulting in remarkable increases in morbidity and mortality in some parts of the world. Globally, there are almost 14 million individuals dually infected and 26% of AIDS related deaths are due to TB, most of them in resource limited settings.

About 13% of the 9,0 million incident TB cases in 2013 were among people living with HIV, 78% of them in Africa.

Dual HIV and TB infection leads to reciprocal interactions that have a significant clinical impact. HIV-induced immunosuppression renders patients more vulnerable to primary or reactivated TB infection, whilst TB is one of the leading causes of mortality in people living with HIV/AIDS. TB is often difficult to diagnose in someone infected with HIV, due to the atypical presentation of the disease. Although the incidence of TB is declining in most EU countries, in Romania, despite recent progress, notification rates remain several times higher than the European mean of 13.5 per 100,000 population.

Treatment in HIV-TB co-infected patients is a challenge due to potential drug interactions between anti TB drugs and antiretrovirals (protease inhibitors) and due to potential cumulative toxicities, especially in injectable drug users, co-infected also with HCV and/or HBV. In this context, this presentation will provide an overview of: general principles of TB treatment in HIV infected patients, WHO classification of TB drugs and how to construct a TB drug regimen, timing of cART and duration of anti TB treatment, new antiTB molecules approved for the treatment of drug resistant TB, potential drug interactions between anti TB drugs and cART and TB treatment in vulnerable groups (HIV infected injectable drug users).

ALGORITHM MONITORING OF PATIENTS WITH HIV/AIDS FOR DETECTING OF PULMONARY TUBERCULOSIS



IOSIF MARINCU*, CLAUDIA CAMBREA**, ȘTEFAN MIHĂICUȚĂ*,
SORINA LAITIN*, ȘTEFAN FRENȚ*, NICOLETA BERTICI*,
PATRICIA POPTELECAN*, VALERIA BICA*, LIVIUS ȚÎRNEA*

*Department of Infectious Diseases, Pulmonology, Epidemiology and Parasitology, University of Medicine and Pharmacy "Victor Babes", Timisoara

**Department of Infectious Diseases, Clinical Infectious Diseases Constanta

Lung tuberculosis (TB) is one of the most common opportunistic infections in patients with HIV/AIDS.

Objectives: Proposing an algorithm for monitoring the patient with HIV/AIDS for early detection of pulmonary tuberculosis in these patients.

Patients and methods: We have enrolled 102 patients with HIV/AIDS, monitored at Clinics of Infectious Diseases in Timisoara and Constanta. In the first-stage diagnosis or suspicion of pulmonary TB was based on elements found in physical examination of patients, radiological changes, and outcome intradermoreaction (IDR) to tuberculin. Selected patients followed the steps of the algorithm based on bacteriological investigations-culture and direct microscopy for bacillus Koch (BK). In all patients, HIV infection was confirmed by Western blot and HIV-1 env DNA gene detection by PCR. CD4 cell counts were also evaluated by flow cytometry in all subjects. Data from individual sheets of patients were then recorded in a electronic database, using Excel program.

Results: We found 5 patients (4.90%) with definite pulmonary TB. Patients who had negative symptoms without radiological changes, and negative TST was considered unlikely cases of TB (n=50). Patients presenting with positive symptoms or radiological change's present or positive TST were considered possible TB cases (n=52). Because changes in HIV+Rx was adenopathy and infiltration type (not ulcers), bacteriological confirmation was reduced to the number of possible TB cases. Clinical symptoms indicative of tuberculosis were significantly more frequent among patients with CD4 <200 (p <0.05). Rx changes have occurred at a significantly lower frequency among persons with low CD4 Li. We have noted that 34 patients were in stage C3 of HIV/AIDS with increased immunosuppression.

Conclusion: The results lead us to recommend the initiation of larger and longer studies to make the arguments necessary to establish early and accurate diagnosis of TB in HIV/AIDS patients.

NORWEGIAN FINANCIAL MECHANISM 2009 – 2014



MIOARA PREDESCU

Senior Specialist in Public Health and Health Management, Project Coordinator

Project RO 19.02:

“Strengthening the prevention and control of HIV/AIDS, HVB, HVC in Romania”

The project “Strengthening prevention and control of HIV/AIDS, HVB, HVC in Romania” is part of the Program “Public Health Initiatives” financed by Norwegian Financial Mechanism 2009 – 2014, having like Project Promoter the National Institute of Infectious Diseases “Prof. Dr. Matei Bals” Bucharest.

The project objectives: is to increase the access of vulnerable (most at risk populations) groups to primary and secondary prevention programs for HIV, HVB, HVC

The project aims: to control HIV, HVB, HVC, by stopping the spread of HIV, HVB, HVC infections among injecting drug users and by increasing the effectiveness of screening for HIV/HVB/HVC to people belonging to high risk groups.

Main activities:

The organization of the Project Management Unit at the level of the National Institute for Infectious Diseases “Prof. Dr. Matei Bals” Bucharest

The production and distribution of a manual/operation tool for harm reduction professionals

Provision of information/ education/ counselling on HIV/AIDS prevention in places where IDUs work and/or live

The provision of protection materials (needle exchange, etc), including the collection of the used syringes.

Involving IDUs in advocacy activities

Testing for HIV/ HVB/ HVC targeted to the Most at Risk Populations;

The development of a National Hepatitis Registry

The development of training programs for medical staff: with focus on family doctors, gynecologist, dermatologists, hematologists, psychologists and nurses;

The development of an information, education, communication campaign against HIV, HVB, HVC.

Project outcomes:

to isolate the epidemiological focal point represented by IDUs and also to improve diagnosis, treatment, health care, adherence, monitoring and evaluation of the target population and also to create and offer social support and prevention interventions for epidemiologically important and vulnerable populations

to insure a high rate of diagnosis and increasing the success rate of treatment, in order to mitigate the possible migration of HIV, HVB, HVC cases from Romania into the European economic area

Partners: ARAS, ALIAT Foundation, PARADA Foundation and Romanian Harm Reduction Network

POSTER SESSION

URINARY TRACT INFECTIONS: ETIOLOGIC SPECTRUM AND SUSCEPTIBILITY TO ANTIBIOTICS



ANDREEA BODEA-ALUCĂ^{*,}, ANCA GEORGESCU^{*,**}, ELOD NAGY^{*,***}, CARMEN CHIRIAC^{*,**}, NINA ȘINCU^{*,**}, VALENTIN BODEA^{***}**

***University of Medicine and Pharmacy of Tîrgu Mureș**

****Clinic of Infectious Diseases I Tîrgu Mureș**

*****Clinical County Hospital Mureș**

Objectives: To evaluate the etiological spectrum and susceptibility to antimicrobial substances of bacterial strains isolated from urine samples.

Material and Methods: We performed a retrospective study on bacterial strains isolated from urine culture during 1.01.2014-31.05.2014 in the Medical Laboratory of the Clinic of Infectious Diseases, Mures County Hospital.

*Results: From a total of 1130 urine samples, 184 (12%) were positive. The prevalence of positive urine culture by calendaristic month ranged between 8 and 17%, with a peak in March. The distribution by gender emphasized clear predominance of cases in women: 155 cases (84%). Most samples were collected from medical departments like Obstetrics - Gynecology (81 cases- 45%) and Infectious Diseases (70 cases -38%). The main etiologic agent isolated from urine was *Escherichia coli* in 119 cases (64.67%), followed by *Enterococcus* strains in 22 cases (11.95%) and *Klebsiella pneumoniae* in 17 cases (9.23%). Various degrees of antibiotic resistance were registered: *Escherichia coli*: ampicillin (73 cases - 61.34%), gentamicin (32 cases- 27.82%), trimethoprim-sulfamethoxazole (31 cases- 26.96%); *Enterococcus* spp: trimethoprim-sulfamethoxazole (21 cases- 100%), streptomycin (12 cases -66.66%), ampicillin (6 cases, 31.57%); *Proteus mirabilis*: ampicillin (3 cases- 100%), nitrofurantoin (2 cases- 66.6%). Multi-drug-resistant strains of *Klebsiella* have been encountered.*

*Conclusions: Urinary tract infections prevail in women, especially in patients from Obstetrics and Gynecology departments. The main etiological agents involved are Gram-negative bacilli, including *E. coli*. The susceptibility to antimicrobial substances of the germs isolated from urine cultures varies. Strains of *E. coli* and *Proteus* register high resistance to aminopenicillins, *Enterococcus* to trimethoprim-sulfamethoxazole and *Klebsiella* strains display multi-drug-resistance.*

Keywords: urinary tract infections, susceptibility to antibiotics

THE ASSOCIATION OF PULMONARY TUBERCULOSIS IN A PATIENT WITH HIV INFECTION. CASE REPORT



ANA LUPU, RAMONA TALE**, RAMONA STANCULETE**,
MIHAELA CAMELIA EPURE**, ALINA MARILENA
LAZARESCU**, VOICHITA LAZUREANU***

***University of Medicine and Pharmacy „Victor Babeș”, Timișoara**

****Hospital for Infectious and Lung Diseases “Victor Babeș”, Timișoara**

Introduction: Tuberculosis is the one of the most common opportunistic infection and a major cause of death in patients with HIV infection in developing countries. HIV-positive patients infected with M. tuberculosis have a 10 times higher risk of developing tuberculosis, compared to uninfected HIV and the probability of reactivation of latent infection increases 20 times. Each disease contributes to morbidity and mortality of the other.

Material and methods: We present a 25 years male patient, diagnosed with HIV in 1999, with the initiation of ARV therapy in 2001. Medical history reveals multiple hospitalizations for HIV-associated and non-associated pathologies. He discontinued the ARV medication between 2012-2014. In January 2015 the patient presents in Clinical Infectious Diseases with dermatitis (clinical diagnosis of Norwegian scabies) and we reintroduced cART, with favorable clinical outcome. After about four months of therapy, the patient presents at the hospital with fever (40°C), weight loss (~ 10 kg in 2 weeks), asthenia, fatigue, diffuse chest pain, dyspnea, coughing with productive mucopurulent sputum for about 2 weeks. Clinical examination revealed: dry generalized skin pigmentation patches, chalky deposits on oro-pharyngeal mucosa, sclera jaundice, hepatomegaly, leg edema, pulmonary changes: MV tightened basal left, crackles disseminated bilateral, without meningeal irritation signs.

Laboratory changes: pancytopenia, anemia, hepatic and renal insufficiency, CD 4 = 1 cells/l.

Chest-ray: supracardiac homogeneous lobe consolidation (pneumonia) with generalized involvement on both interstitio-alveolar lung fields, upper right perihilar macroadenopathy, without pleural effusion.

Smear: A = 1+; B = +; mycobacterium - in working cultures.

Tuberculostatic treatment was initiated. The evolution was unfavorable: weight loss, with associate hemoptoic sputum, bloody stools, skin and mucous with intense jaundice, respiratory failure phenomena, kidney failure, liver failure and death.

Conclusions: Tuberculosis is a leading cause of morbidity and mortality among patients with HIV. HIV increases the risk of reactivation of latent TB infection and active TB disease progression. Interruption of ARV treatment is the main reason of disease progression for our patient.

Keywords: pulmonary tuberculosis, HIV infection, non-adherence to cART.

RISK OF MOTHER-TO-CHILD TRANSMISSION OF HIV



CARMEN CHIRIAC, IRINGO ZAHARIA-KEZDI, BRÎNDUSA ȚILEA, ANCA GEORGESCU, CRISTINA GÎRBOVAN, ANDREA INCZE, NINA ȘINCU, MANUELA CUCEREA

University of Medicine and Pharmacy, Tirgu-Mures

Objectives: to assess the risk of mother-to-child transmission of HIV infection and peculiar features of newborns from HIV-positive mothers.

Material and methods. We performed a retrospective, descriptive study concerning the status of HIV infection in female patients at fertile age from Mures Regional Center and in their newborns. We correlated the level of HIV-RNA plasma viral load and CD4+ T-cells count of the mothers to the risk of infection in their newborns. We assessed the role of antiretroviral therapy during pregnancy, as well as that of antiretroviral prophylaxis in newborns.

Results. At present time, 56 children born from HIV-infected mothers are monitored in Mures Regional Center, out of which 3 are HIV-positive. Most pregnant patients belong to the Romanian cohort (89%). The risk of mother-to-infant transmission of HIV was 5% in our study. The most important risk factors were: mother's immune and virologic status and the lack of antiretroviral therapy during pregnancy. All children underwent antiretroviral prophylaxis. We noticed low birth weight (average 2565 g). The most important birth defects were cardiac malformations – septal defects.

Conclusions. Early diagnosis of HIV infection in pregnant women and following the prophylactic protocol regarding mother-to-child HIV transmission are absolutely necessary.

Key-words: human immunodeficiency virus, pregnant patient, mother-to-child HIV transmission

OPPORTUNISTIC INFECTIONS AND IMMUNE RECONSTITUTION INFLAMMATORY SYNDROME IN A LATE PRESENTER PATIENT



OTTILIA DIMENY*, IOANA-RALUCA TODORAN*, ZS. RAJNA*, E. DEZSI*, KATALIN PUSOK, ERZSEBET-IRINGO ZAHARIA-KEZDI**

*Infectious Disease I Clinic, Targu-Mures

**University of Medicine and Pharmacy, Targu-Mures

Objectives: Presentation of a HIV positive patient, a late presenter with multiple comorbidities and with immune reconstitution inflammatory syndrome (IRIS).

Material and method. Case report

Male patient, born in 1978 from an urban area was admitted to our hospital with fever, headache, asthenia, balance disorder, confusion. Neuroimaging revealed cerebral lesions, which were suggestive for toxoplasmosis. Laboratory investigations: ELISA and Western Blot confirmed HIV infection with very low CD4 cell count (<50 cells/ μ l). The microscopic examination for sputum confirmed infection with Mycobacterium tuberculosis, the culture positive for Streptococcus pneumonia. The cerebrospinal fluid examination through latex agglutination was positive for cryptococcal antigen, cranial MRI showed multiple brain abscesses with perilesional edema. Antiretroviral, antifungal, anti-mycobacterial treatment and PCP prophylaxis was initiated. After a few days he developed fever, pneumococcal pneumonia and herpes zoster. The chest X-ray was suggestive for lung cancer, which was excluded through thoracic CT scan, tumor markers and histopathological examination.

Results: The final diagnosis was C3 stage AIDS, pulmonary tuberculosis, cryptococcal meningoencephalitis, pneumococcal pneumonia, immune reconstitution inflammatory syndrome (.Herpes zoster, pneumonia). The outcome was mildly favorable under complex therapy.

Conclusions: Late presenter- HIV infected patients with severe immunodepression must be investigated for every possible opportunistic infections. The evolution and treatment often is compromised by IRIS. The adherence to the complex treatment and timely diagnosis is essential for a favorable outcome.

Keywords: HIV, opportunistic infection, late presenter, IRIS

SUBCLINICAL ATHEROSCLEROSIS AND THYROID CARCINOMA IN A YOUNG HIV INFECTED PATIENT- CASE REPORT



DUMITRESCU FLORENTINA^{*,}, CUPȘA A^{*,**}, GIUBELAN L^{*,**},
CUPȘA DINA MARIA^{**}, STOIAN ANDREEA CRISTINA^{*,**},
NICULESCU IRINA^{*,**}, STĂNESCU MARIANA^{**}, COROBEA
ALEXANDRA^{**}**

***University of Medicine and Pharmacy from Craiova**

****"Victor Babes" Hospital of Infectious Disases and Pneumology from Craiova**

We present the case of a patient (Pt) of 26 years old, diagnosed with HIV infection in June 1991 (horizontally infected during early childhood), classified as B2 stage in 1996 ($CD_4=263$ cells/mm³) when he started antiretroviral treatment (ARV), under surveillance of Craiova Regional Center, with minor health problems (respiratory and digestive) and no clinical AIDS events until present. He followed ARV monotherapy during 1996-1997, dual therapy between 1997-1999 and triple therapy (PI based) starting from 1999; in 2002 due to clinical, immunological and virological failure he started a new regimen (d4T+3TC+LPV/r) under which the viral load (VL-HIV) becomes undetectable (until 2011), with a CD_4 count above 350 cells/mm³ since 2004, but having mixed dyslipidemia (with severe hypertriglyceridemia); however clinical exams and cardiological evaluation did not detect evident alterations. He followed low fat and carb diet, physical exercises and lipid-lowering drugs, with an undulating lab value evolution since 2007 (triglycerides level > 350 mg/dl and low HDLc). He is a non smoker, has not a familial history of cardiovascular diseases and continued a balanced lifestyle. A complex evaluation performed in September 2011 found a hs-PCR level of 1.78 mg/l, D-dimers level of 0.29 μ g/ml FEU and an Intima-media thickness (IMT) of 0.78 mm (average of 5 measurements), suggesting a moderate cardiovascular risk and subclinical atherosclerosis. He started lipid-lowering (statins + fibrates) and anticoagulant therapy. Ultrasound examination of the carotid artery also evaluated his thyroid gland and found a nodule on the left lobe. After complex endocrine evaluation in september 2012 he underwent thyroid surgery (total removal of the gland), radiotherapy and iodine administration folowing the diagnosis of thyroid carcinoma; he also started hormone replacement therapy. Due to persistent dyslipidemia the ARV has been changed to ABC/3TC + RAL which normalised the lipid values; he also showed a CD_4 count > 400 cells/mm³ and undetectable HIV viremia. The Pt remains to be monitored by our clinic.

Keywords: HIV, atherosclerosis, carcinoma

BENEFITS OF USING LINEZOLIDE WITH CEFTAROLINE COMPARED TO OTHERS ANTIBIOTICS ASSOCIATIONS IN SPODYLODISCITES AND PSOITES



MIHNEA HURMUZACHE^{*,**}, MADALINA POPAZU^{*}, GEORGIANA ENACHE^{*}, CATALINA LUCA^{*,**}

^{*}Section 1 of Infectious Diseases, Clinical Hospital of Infectious Diseases “Sfanta Parascheva” Iasi

^{**}University of Medicine and Pharmacy “Grigore T. Popa” Iasi

Objective – the benefits of the first line therapy with Linezolid and Ceftaroline for a 14 days period, in patients with spondylodiscitis and psoitis, compared with the association including Vancomycin/Linezolid and fluoroquinolones or Clindamicine and fluoroquinolones (most frequent associated therapy).

Materials and method: retrospective case study involving 15 patients diagnosed with spondylodiscitis and psoitis, at “Sf. Parascheva” Infectious Diseases Hospital in Iasi, between 2012 and 2014, that received treatment with: 6 cases - Linezolid/Vancmicin and fluoroquinolones, 5 cases - Clindamicine and fluoroquinolones and 4 cases with Linezolid and Ceftaroline.

Discussion: Spondylodiscitis is an infection of the intervertebral disk and adjacent vertebrae, with or without associated epidural or psoas abscesses.

Psoitis inflammation is regarding psoas muscle or it's sheath.

The most frequent bacterial pathogen is Staphylococcus aureus, with an incidence over 80%. The site of primary infection was lumbar. In all cases therapy was only medical. The pathogen was detected in about half of the cases – more often in acute than in chronic cases. The main methods to diagnose a spondylodiscitis are magnetic resonance imaging (MRI), biopsy and microbiological tests such as PCR to determine an infectious cause.

In our study there were isolated in 6 cases (out of 15) – 2 MRSA and 4 MSSA (the pathogen was isolated local or in blood culture), in the other 9 the diagnosis was based on clinical and imagistic criteria.

Results and conclusions: there have been differences in favorable evolution or duration of therapy using associations including Linezolid and Ceftaroline for the first 14 days unrelated to ulterior therapy association up to 8 weeks. Success rate was 100% compared with 55% in other cases.

Key words: Linezolid/Ceftaroline, staphylococcal spondylodiscitis, psoitis, other antistaphylococcal antibiotics association.

INFECTIVE ENDOCARDITIS. CASE REPORT



MIHAELA CAMELIA EPURE, ALINA MARILENA LAZARESCU**, ANA LUPU**, RAMONA STANCULETE**, RAMONA TALE**, VOICHITA LAZUREANU***

***University of Medicine and Pharmacy „Victor Babeș” Timișoara**

****The “Victor Babeș” Hospital for Infectious and Lung Diseases, Timisoara**

Introduction: Infective endocarditis is a condition that can produce vegetation on endocardial surface of the heart and usually involves a healthy heart valve. Infective endocarditis with MRSA attack on free heart valves and may be potentially fatal in 25-47% of cases by bacteremia within a few days or a few weeks of heart failure.

Material and methods: We report a case of a 55 years old female patient known with ischemic stroke with left her with a motor deficit (2004, 2010), epilepsy (2004), grade III essential hypertension with very high cardiovascular risk(2011). She was transferred to us from the rheumatologic department with the diagnostic of undifferentiated collagenosis, with a history of approximately 3 weeks of fever (38.5°C), back pain, bilateral numbness legs, marked fatigue, weight loss and loss of appetite. On admission we found: pale mottled skin, white deposits on the tongue, rich adipose pannicle (BMI=31,34 kg/m²), BP=119/76mmHg, no clinical signs of meningeal irritation. They were conducted laboratory tests that showed values of L=8950/ul with 87.2%neutrophils, ESR=130mm/h, CRP=167mg/l, Hb=9g/dl, Ht=26.8%. Chest radiography, smear analysis for mycobacterium also preliminary infirmed the diagnosis of a pulmonary tuberculosis. Blood cultures were performed and revealed the presence of MRSA. During hospitalization fever persisted and cardiac stetacustic changes were detect: new regurgitant murmurs. The cardiologist confirmed the presence of vegetation on the aortic valve, severe aortic regurgitation, mitral regurgitation grade II, heart failure NYHA II / IV. We initiated the antibiotic treatment with vancomycin (2g bid). After 4 weeks, surgery was performed (medical indication of mechanical prosthetic valve in the aortic position). Postoperatory the patient continued antibiotics for another 2 weeks with subsequent favorable evolution.

Conclusions: Infective endocarditis developed on native valve manifested only with fever, in absence of an infection outbreak, is later taken into consideration. The clinical symptoms and ecografic changes of valvular lesions appear also later. There is a dispute about the incidence of rheumatic manifestations of infective endocarditis, probably due to their low frequency and the absence of a constant criteria in the diagnosis of infective endocarditis.

Keywords: fever, infective endocarditis, MRSA, vegetation, aortic regurgitation, blood cultures.

PSEUDOMONAS AERUGINOSA VENTRICULITIS – CASE REPORT



**MIHAELA ZAHARIA*, LAURA ENE*, DELIA STANCIU*,
CORNELIU PETRU POPESCU*,**, SIMIN AYSEL FLORESCU*,**,
EMANOIL CEAUSU*,****

***Dr. Victor Babes Clinical Hospital of Infectious and Tropical Diseases, Bucharest**

**** University of Medicine and Pharmacy “Carol Davila” Bucharest**

Background: Pseudomonas aeruginosa is not a common cause of meningoencephalitis, and occurs mainly after neurosurgical interventions. Ventriculitis (inflammation of the ventricular fluid and lining of the ventricles, usually in association with obstruction to cerebrospinal fluid flow) is a common complication of gram negative bacilli (GNB) meningitis.

Case report: Female aged 68 had headache with a fever for 2 days, with onset of disorientation and mild dysarthria and vomiting episodes. The patient was admitted into the infection diseases unit of a regional hospital (Valcea County Hospital) where the symptomatology progressively worsened which suggest a neurological infection and the patient is referred to our hospital. The medical history of the patient shows diabet mellitus and cardiac diseases (hypertension, ischemic cardiac disease, dyslipidemia). Three weeks before symptomatology started the patient was hospitalized in a cardiology unit, were she received parenteral drugs without any interventional maneuver or surgycal intervention. No cranial traumas were presented. After clinical and biological investigations (including the CSF's characteristics) the diagnostic of Pseudomonas aeruginosa meningitis was formulated.

Findings on lumbar puncture (LP) (include CSF pleocytosis 460 cells, with a predominance of polinuclear cells, and elevated protein=2.67 g/l and decreased CSF glucose= 0.3g/L) and CSF Gram stain reveals GNB meningitidis and an antibiotics treatment was started with Meropenem and Ciprofloxacin i.v., for 48 hours and switch at Ceftazidim and Ciprofloxacin iv after the bacterial identification and antibiograma for another 4 weeks. Findings on repeat LP at 4 weeks were still modified (include CSF pleocytosis of 161 cells, with a predominance of polinuclear cells, and elevated protein=1.23 g/l and decreased CSF glucose= 0.25 g/L, with a negative CSF culture), therefore a cerebral IRM was performed which reveals cerebral lateral ventriculitis. The neurosurgical evaluation recomends following the antibiotal treatment without neurosurgical intervention. At the existent antibiotherapy was associated amikacin for a total period of treatment of 8 weeks, with normal clinical future and pseudonormalization of the CSF's aspects. The clinical and biological follow up at 14 days is normal.

Conclusions and discussion: There is unusual that epidemiological history of the patient with a Pseudomonas aeruginosa neurological infection is not including neurosurgical intervention, cranial trauma or otic pathology, known as risk factors of this bacterial etiology. Following the antibiotic treatment for 8 weeks, the patient's clinical evolution was favorable without surgical intervention. Ventriculitis is a common complication of Pseudomonas aeruginosa meningitis which increases the antibiotics duration for at least 6-8 weeks (and thus the lenght of stay). In several cases the adminitration of intraventricular drugs was necessary because of the worsened evolution under the intravenous therapy. This approach prevents the risk of increased secondary complications.

Keywords: meningoencephalitis, ventriculitis, Pseudomonas aeruginosa

TRICHINOSIS, EVOLUTIVE ASPECTS AND PARTICULAR CASES



MIRANDOLINA PRIȘCĂ*, DANA NEGRU**, MARIANA NAGY***

*"Vasile Goldiș" West University, Arad

** Public Health Department, Arad

***"Aurel Vlaicu" University, Arad

Objectives. Especially important as zoonotic disease, efforts must be sustained for elimination of trichinosis in the food chain. Early diagnosis in human is difficult in the absence of pathognomonic signs. Evolution of disease is related to comorbidities in elder patients.

Material and methods. We analyzed 63 trichinosis cases to determine biological parameters, gender and age distribution and relative risk for severe forms in particular cases. Data were processed SPSS 17.0 for Windows and MedCalc.

Results. 63 human trichinosis cases is not exceptional for Arad county, in the last 10 years have been encountered outbreaks with more than 100 cases. The average age of patients was 31 with extreme 2-74, with equal gender distribution. Over half of the patients required hospitalization. Disease evolution was mild for 54%, medium for 41% and severe for 5%. Average hospital days was 6 with extreme 2-13, with 43% of children hospitalized compared to 60% of adults. Edema and myalgia occurred in 33% of cases, asthenia and headache in 31% of cases and lack of appetite and fever in 27%. More than half of hospitalized cases had more than 5 symptoms and eosinophilia above 20%. IgG for *Trichinella* was positive in 13,5% of cases. Relative risk for medium and severe forms of trichinosis was 13 times higher for patients with comorbidities as diabetes, coronary heart disease, hypertension, obesity.

Conclusions. Trichinosis in humans is not only a public health problem but requires special care for elder patients with diabetes, coronary heart disease, hypertension, obesity.

Keywords: trichinosis, relative risk, comorbidities

LONG TERM IMMUNOSUPPRESSION AND ITS SECONDARY INFECTIOUS COMPLICATIONS IN A PATIENT WITH RHEUMATOID ARTHRITIS – CASE REPORT



RAMONA ȘTEFANIA POPESCU^{*,}, RODICA BACRUBAN^{**},
ADRIAN STREINU-CERCEL^{*,**}**

*** University of Medicine and Pharmacy “Carol Davila” Bucharest**

****National Institute for Infectious Diseases “Prof. Dr. Matei Balș”, Bucharest**

Introduction: Rheumatoid arthritis (RA) is a chronic inflammatory disorder, affecting typically the small joints. It has a progressive course and if left untreated, leads to a premature loss of joint function. The disease itself implies an immunosuppressive state which is very much increased secondary to therapy.

Anti-tumor necrosis factor (anti-TNF) agents have revolutionized the treatment of RA. These drugs confer a small but significant risk of serious infections, especially during the first months of treatment.

Case report: We report the case of a male patient, 57 years old, diagnosed 19 years ago with seropositive RA who along the way developed many infectious complications.

During his disease course he received treatment first with methotrexate in progressively increasing doses, to which leflunomide was subsequently added. Due to unfavorable outcome, treatment was switched to adalimumab, with hydroxychloroquine being added 6 months later. Under this treatment he developed left shoulder septic arthritis (SA) with Gram-negative bacilli. Adalimumab was stopped, he underwent surgery and antibiotherapy (Imipenem+Cilastatin). In the following months, he had two relapses, first with Citrobacter Spp, second with E. Coli, which needed long-course antibiotherapy (oral and local instillations) and surgical treatment. He restarted treatment with high doses of methotrexate, but recurrent urinary tract infections with E.Coli prompted for a dose reduction.

At the moment, the patient has chronic suppuration of the right hallux, with positive cultures for Staphylococcus aureus methicillin-resistant, for which he received many antibiotic courses, with good clinical response but with purulent discharge when the treatment is stopped.

Conclusions: SA is a serious medical condition that, even with prompt treatment, can lead to irreversible joint damage and has a death rate of around 10%. The risk of SA in an RA patient, irrespective of therapy, is increased by 4–15-fold, anti-TNF therapy is associated with a doubling in the risk of SA.

In a patient with a long history of immunosuppression infectious complications are expected so timely diagnosis of secondary infections is necessary in order to maximize the benefits and reduce the risks associated with immunosuppressive therapy.

Acknowledgement: Partially supported through POSDRU/159/1.5/S/137390.

Key-words: immunosuppression, infectious complications, rheumatoid arthritis

TREATMENT OF INVASIVE MENINGOCOCCAL DISEASE – A 18 YEAR REVIEW



ROXANA ELENA NEMESCU, MIHNEA HURMUZACHE, CARMEN MANCIUC, CĂTĂLINA MIHAELA LUCA

Infectious Diseases Department, University of Medicine and Pharmacy, Iași

Objective: To describe the therapeutic findings in patients with invasive meningococcal disease (IMD) admitted to the Hospital of Infectious Diseases of Iași.

Material and methods: retrospective review of medical records (concerning etiological and pathogenic treatment) of all patients with IMD admitted in our hospital, from January 1994 through December 2011.

Results: In the studied period, 323 cases of IMD were registered: 79.6% - meningococcal meningitis (MM) and 20.4% - meningococemia (MCC). Penicillin G was used in more than half of the cases of IMD (54.8%), 3rd generation cephalosporins (G3C) in 24.15% and Ampicillin in 16.1%. If in the first half of the studied interval, the most frequently used was Penicillin G, in the second half, an obvious increase of the use of G3C as a first intention therapy could be noticed. Of the 92 strains of Neisseria meningitidis tested in Penicillin G, 87 were sensitive (94.6%), 4 moderately sensitive (4.3%) and a single one resistant (1.1%). In the case of Ampicillin, 61 sensitive strains were registered (89.7%), 5 moderately sensitive (7.4%) and 2 resistant (2.9%). All strains tested in Amoxicillin (4, 100%), G3C (68, 100%) and Meropenem (11, 100%) were sensitive to these antibiotics. Sensitivity to Penicillin was maintained constant along the studied period until 2011, when all tested strains had intermediary resistance to Penicillin. The only strain resistant to Penicillin was registered in 2001. Corticotherapy was used in 47.4% of the cases of IMD. Despite the increase of the use of corticotherapy in the past 10 years compared to the first part of the studied interval (34.3% vs. 68%) ($\chi^2=34.8$, $p<0.0001$), the survival rate in IMD was better in patients who did not receive corticotherapy. Thus, the frequency of deaths in the group with corticotherapy was 15.69%, a significantly higher value compared to their frequency in the case of absence of corticotherapy (1.76%) (Pearson $\chi^2=20.4$, $p=0.00001$). The risk of death (odds ratio) in the case of administering corticotherapy in IMD was 10.36 times higher (95% CI: 2.88 - 44.19) than in the case of not administering corticotherapy. In MM, the survival rate of patients was also better in those without corticotherapy compared to those who received this treatment (99.3% vs. 97.1%), but this difference was not statistically significant (Pearson $\chi^2=1.96$, $p=0.161$, NS). In MCC, the survival rate was significantly higher in those not treated with cortisone compared to those who received this treatment (89% vs. 56%) ($\chi^2=6.14$, $p=0.013$). The risk of death (odds ratio) in the case of administering corticotherapy was 6.22 times higher for MCC (95% CI: 1.16 - 44.11) and 4.44 times higher for MM respectively (95% CI: 0.41 - 42.37). The treatment of shock was necessary in 20% of the patients with IMD. In MCC, 63.6% of the patients were treated for shock compared to only 8.9% in MM ($\chi^2=97.7$, $p<0.0001$). 55.8% of the patients with shock who received corticotherapy survived, compared to 76.9% of those with shock, but who did not receive corticotherapy. Although it was noted that in the case of not administering corticotherapy in the therapy of shock, the survival was better, the differences were not statistically significant ($\chi^2=1.93$, $p=0.163$).

Conclusions: For the etiological treatment of cases of IMD, we recommend the use of C3G for a period of 7-10 days. Although the meningococcus maintained its sensitivity to Penicillin in our geographical area, the signalling even of a small percentage of moderately sensitive/resistant strains, determines us to refrain from its recommendation as a first-line treatment of IMD, and it shall be used only in case of confirmation both of the meningococcal etiology and of the germ's sensitivity to Penicillin. Because the treatment with cortisone did not prove its efficiency in IMD, the utility of administering steroids remains controversial.

Keywords: invasive meningococcal disease, Neisseria meningitidis, 3rd generation cephalosporins, Penicillin, corticotherapy.

RECURRENCE FREQUENCY IN CLOSTRIDIUM DIFFICILE INFECTION IN HOSPITAL OF INFECTION DISEASES AND NEUMOPHYSIOLOGY “V.BABES” TIMISOARA



**SORINA LAITIN, I. MARINCU, E. POPOVICI, LUMINITA
BADITOIU, MARIANA ANGHEL**

***Epidemiology Department, University of Medicine and Pharmacy “Victor Babes” Timisoara**

****Infectious Diseases Department, University of Medicine and Pharmacy “Victor Babes”
Timisoara**

Our hospital studies on a number of 9 patients between 1.03.2014- 1.03.2015 diagnose with Enterocolitis with Clostridium Difficile, who have recurrence of a total number of patients 154 Hospitalized for the same diseases in the same period.

The age of the patients are between 30-76 years, 7 for the urban society, 2 for the country society, most of them male, who follow an aggressive antibiotics treatments or have severe immunosuppressive after chronic diseases.

As a conclusion, prudence and limitation required in antibiotics administration, as well as isolation, intensive cleaning measure and decontamination of the surfaces of hospital environment to provide primary and secondary prevention of nosocomial infection with Clostridium Difficile.

OSTEODISCITIS – ETIOPATHOGENIC ASPECTS AND THERAPEUTIC MANAGEMENT



VALENTINA SIMION*, M.HOMOS, C. BARBULESCU**, A. DOGARU**, A.M.POPESCU**, S. SMADU**, M. NICA**, EMANOIL CEAUSU***

***Victor Babes Infectious and Tropical Diseases Clinic Bucharest**

****Victor Babes Infectious and Tropical Diseases Clinical Hospital Bucharest**

Introduction – Osteodiscitis represents an important chapter in the pathology of vertebral disc infectious diseases, reflecting the predisposition of this anatomical level for illnesses as well as the aggressiveness of surgical interventions

Objectives – The documentation of etiopathogenic aspects in patients diagnosed with osteodiscitis, current therapeutic management

Materials and Method – A retrospective study on 57 cases of osteodiscitis, hospitalized at Victor Babes Infectious and Tropical Diseases Clinic between 2014 and 2015

Results:

The predominance of the male sex can be observed (63%);

The average age was 59.7 years, with ranges between 20 years old and 80 years old;

The most frequent localization was at lumbar level (39%)

Associated pathologies included varied diseases of the vertebral column, surgical interventions at this level, diabetes mellitus, obesity;

The pathogenic agent most frequently identified was Staphylococcus Aureus (14%), followed by Enterococcus and Acinetobacter;

In 50% of the cases, osteodiscitis developed as post-operative, after surgeries for varied diseases of the vertebral column (abscess, hernia, epiduritis);

The most frequent therapeutic scheme involved the association of Cephalosporins and Fluoroquinolones in 42% of cases, and Cephalosporins associated with Vancomycin (26%);

Conclusions – Surgical interventions involving the vertebral column represent an important risk factor; diabetes and obesity represent associated risk pathologies; the necessity of physical and therapeutic examination and investigation of inflammation markers and imaging studies.

Keywords: osteodiscitis, therapy, etiology

NOSOCOMIAL URINARY TRACT INFECTIONS – ETIOLOGY AND THERAPEUTIC MANAGEMENT



VALENTINA SIMION*, M.HOMOS, C. BARBULESCU**, A. DOGARU**, A.M.POPESCU**, S. SMADU**, M. NICA**, EMANOIL CEAUSU***

***Victor Babes Infectious and Tropical Diseases Clinic Bucharest**

****Victor Babes Infectious and Tropical Diseases Clinical Hospital Bucharest**

Introduction: Urinary tract infections, regardless of their localization, represent one of the most frequent pathologies, unrelated to age. Nosocomial urinary tract infections represent an important problem regarding therapeutic approach and clinical development.

Objectives: The presentation of certain etiological, development and therapeutic aspects of urinary tract infections.

Materials and Methods: A retrospective study on 180 patients, hospitalized between 01.01.2015 and 31.12.2014 at Victor Babes Infectious and Tropical Diseases Clinic. The cases involved in the study were selected in accordance with the following case definition: patients with past surgical interventions or urinary catheterization, with clinical or laboratory elements.

Results:

Most patients were female (69.4%);

age was limited between 30 years old and 85 years old.

Associated risk factors were surgical interventions (40.5%), urinary catheterization (24.4%).

Most frequent pathological agents involved were E. Coli (60.5%), Klebsiella Spp. (17.2%), Enteroccus Spp. (12.12%) and Proteus (6.11%).

52 multi-drug resistant strains were identified. Furthermore, 31% of cases were recurrent urinary infections.

Monotherapy was introduced in 60% of cases and bitherapy in 40% of cases. Fluoroquinolones, III/IV th generations Cephalosporins and carbapenems were utilized.

Conclusions: Nosocomial urinary infections are a reality in modern medical practice, raising therapeutic problems and involving high hospitalization costs. One third of cases are represented by multi-drug resistant strains.

Keywords: nosocomial infections, antibiotic resistance, therapy

APPRECIATION OF THE LIVER DAMAGE SEVERITY IN HIV-HBV COINFECTED PATIENTS



ZS-J. RAJNA*, HELGA KATAI**, FRANCISKA KRISTÁLY**, D. ZAHARIA-KÉZDI**, INCZE ANDREA***, ERZSÉBET IRINGÓ ZAHARIA-KÉZDI***

*Infectious Diseases Clinic County Hospital I, TgMureș

**UMPH, TgMureș, 3. UMPH, TgMureș, Infectious Diseases Clinic County Hospital I, Romania

Objectives. Coinfection with Human Immunodeficiency Virus (HIV) and Hepatitis B Virus (HBV) presents a challenge for clinicians, because coinfecting patients may progress to end-stage liver disease more rapidly than HBV-monoinfected patients. The aim of this study is to evaluate the liver damage at HIV positive patients coinfecting with HBV monitored in the 1st Infectious Diseases Clinic of Tg. Mures.

Material and methods. We performed a retrospective cross sectional study to evaluate the liver damage, calculated with APRI-score (Aspartat Aminotransferase, AST to Platelet Ratio Index) in HIV-HBV coinfecting patients. If the APRI score was less than or equal to 0.5, we considered no fibrosis to be present or just a little, if APRI score was equal to 1.5 or above, we considered cirrhosis to be probable, and for APRI scores between 0.5 and 1.5, the indications lead to progressive fibrosis stages. The study group was represented by 50 coinfecting patients, 28 males, median age 27, 3 with AgHBe, 40 from Romanian cohort. We correlated the APRI score with AST, ALT (alanine transaminase) and prothrombin index (IP). Mann Whitney test was used for statistical analysis.

Results: 28 patients had APRI score below 0.5 (group I), 14 between 0.5-1.5 (group II), and 8 above 1.5 (group III). Group I averages: AST 25,03UI/L, ALT 26,75UI/L, IP 67%. Group II averages: AST 39UI/L, ALT 44UI/L, IP 63%. Group III averages: AST 600UI/L, ALT 850UI/L, IP 46%. Significant statistical difference was found between the three groups regarding GOT ($p=0,0047$), GPT ($p=0,0032$) and PT% ($p=0,0494$).

Conclusions: Group 2 and 3 together constitute 44% of our tested patients. This means that 44% suffer either from progressive fibrosis or cirrhosis. Further testing is required to determine whether APRI score can be used on a daily basis or not.

Keywords co-infection HIV Hepatitis B virus, APRI-score, fibrosis, cirrhosis

DISSEMINATED TUBERCULOSIS IN A HIV PATIENT NON- ADHERENT TO ANTIRETROVIRAL THERAPY. CASE REPORT



IOANA-RALUCA TODORAN*, OTILIA DIMENY*, ZSOLT RAJNA*¹, ANDREA INCZE**, CARMEN CHIRIAC**, ERZSEBET-IRINGO ZAHARIA-KEZDI**

*Infectious Disease I Clinic, Targu-Mures

**University of Medicine and Pharmacy, Targu-Mures

Objective: Central nervous system (CNS) tuberculosis represents the most severe form of tuberculosis, that associate high rate of morbidity and mortality. We present a case of dissemination of multi-drug resistance tuberculosis (MDR-TB) in lung, genital organs and CNS in a young patient with HIV infection and non-adherence on the antiretroviral therapy.

Material and method. Case report

A 25 year-old, male patient was admitted for insidious symptoms that comprise cough, headache, sweat, weight loss, fatigue. CD4 T-cells counts were 68 cells/mm³ at admission. Chest x-ray showed micronodular aspect in both lung areas. Mycobacterium tuberculosis was positive in sputum, the antibiogram revealed bacilli resistance at isoniazide and rifampicin. The examination of the cerebrospinal fluid (CSF) revealed a lymphocyte count of 1600/μl, hipoglycorrhachia (16 mg/dl), hiperproteinorrhachia (326.8 mg/dl). Ziehl Neelsen staining showed no acid-fast bacilli in CSF, also negative results for common germs or fungi. Furthermore, Lowenstein Jensen culture were positive for Mycobacterium tuberculosis. After 18 days from admission, the patient developed disorientation, confusion, drowsiness, tetraparesis. MRI examination reveal hydrocephalus and periventricular edema.

Results: HIV-infected patient with severe-immunodeficiency was diagnosed with disseminated MDR-TB, hydrocephalus, Wasting syndrome. Despite anti-TB treatment, the patient's condition deteriorated progressively towards coma, with a Glasgow Coma Score of 3 points. He was transferred to the intensive care unit, where he developed cardio-respiratory arrest. 48 days after admission he died.

Conclusions: Tuberculosis represents an important HIV-associated opportunistic infection. Immunodeficiency and the lack of adherence to antiretroviral therapy leads to disseminated tuberculosis. CNS tuberculosis is associated with an unfavorable prognosis and high mortality.

Keywords: Multi-drug resistance tuberculosis, HIV infection, disseminated tuberculosis.

VERTICAL HIV TRANSMISSION IN ARAD COUNTY



DANA NEGRU*, VICTOR TOMA, IOANA JURCĂ**,
MIRANDOLINA PRIȘCĂ**, LILIANA BRAN**, GHEORGHE NINI**,
MARIANA NAGY*****

***Public Health Department, Arad**

****"Vasile Goldiș" West University, Arad**

*****"Aurel Vlaicu" University, Arad**

Objectives. HIV/AIDS is, effectively, a pandemic with reported cases in every continent. In some countries, studies show that HIV/AIDS case reporting is done in about 90% but around the world HIV/AIDS are incomplete reported, and route of transmission remains unknown. Vertical and sexual transmission are both concerning public health services, being ourdays the main route for new HIV/AIDS infections.

Material and methods. All Western blot HIV/AIDS confirmed cases between 1990-2014, were analysed in an observational, retrospective, longitudinal study, using SPSS 12.0 for Windows and MedCalc.

Results. Between 1990-2014 were declared 489 HIV/AIDS cases. The route of transmission is unknown for 10% of cases, 62 % were nosocomials, 22.13% of cases were sexually transmitted and 5% vertically, from mother to child. For about 26% of patients we have no longer data, being lost from evidence and 41% are deceased. Currently are 160 persons in files. Life expectancy has increased since 1998, with the introduction of HAART. Sexual and vertical transmission path are worrying after 2000. There are 35 HIV/AIDS infected couples, which have procreated 18 children, 11 HIV seronegative and 7 HIV positive. Of the seven HIV positive children, 6 are from untreated mothers, the seventh represent a treatment failure.

Conclusions. The risk of HIV/AIDS transmission in Arad is now mainly sexually and vertically. The role of the family physician and obstetrician in monitoring HIV-infected patients and their close contacts is crucial to limit infection and increasing the life expectancy, especially in relation with procreation.

Keywords: vertical transmission, treatment failure, HIV couples

ACUTE PNEUMOCOCCAL MENINGITIS IN A IMMUNOCOMPROMISED PATIENT



ANDREEA ARDELEANU*, OVIDIU ROSCA, DANIELA MIHALCEA*, IULIANA CARAMANGIU*, MONICA CIALMA**, OANA PLAVITU*, OANA SACEANU*, PATRICIA POPTELECAN*, IOSIF MARINCU****

***Department of Infectious Diseases I, Clinical Hospital of Infectious Diseases and Pneumophthysiology "Victor Babes" Timisoara**

****Department of Infectious Diseases I, University of Medicine and Pharmacy "Victor Babes" Timisoara**

Objective: Case presentation of a 63 years old woman with Pneumococcal meningitis and Type II Diabetes.

Material and methods: We report the case of a patient admitted in our Department in 23.04.2015 with acute onset symptomatology that included headache, high fever, severe psychomotor agitation, neck stiffness and altered mental state. A native brain CT was performed that revealed a mild cerebral edema. At the admission in the Infectious Diseases Department a LP was performed. The CSF was hypertensive, opalescent and characterized by a strongly elevated white blood cell count (9600 cells/ μ l) with predominance of PMN (90%), elevated protein level (594.7 mg/dl), increased lactate (193.68 mg/dl) and decreased glucose CSF/blood ratio. Latex-agglutination based rapid tests were performed and were positive for Streptococcus Pneumoniae. Peripheral white blood cells, serum C-reactive protein, ESR and procalcitonin were elevated. Two days after admission she developed focal neurological signs, epileptic seizures, impaired consciousness and coma. Prior to antibiotic treatment a blood culture was obtained (revealed no bacterial development) and the CSF culture was positive for Streptococcus Pneumoniae.

Results: Under treatment with Ceftriaxone in high doses the evolution was unfavorable despite the sensibility "in vitro". After three days of treatment we switched therapy to Meropenem and Vancomycin, high dose corticosteroids (dexamethasone) and Mannitol with a favorable evolution. As a complication she developed walking aphasia.

Conclusions: Pneumococcal meningitis is associated with high mortality and morbidity rates in immunocompromised adults. We underline the importance to improve pneumococcal vaccine coverage among certain populations of immunocompromised adults

CEREBRAL TOXOPLASMOSIS IN A PATIENT WITH HIV/AIDS



BOGDAN CATALIN TRINCA, MANUELA CURESCU, BIANCA CERBU, PATRICIA POPTELECAN, OANA SACEANU, LAURENTIU VOCHITA, VALERIA BICA, IOSIF MARINCU

Department of Infectious Diseases, Pulmonary and Parasitology, University of Medicine and Pharmacy, „Victor Babes” Timisoara

Objectives: Presentation of a clinical case of cerebral toxoplasmosis in a patient with HIV infection stage C3.

Patients and methods: The authors present the case of a patient of 31 years diagnosed with HIV in 2013, noncompliant of medication, revalued in february 2015 (when set ART), the current hospitalized in Infection Disiase Clinic I Timisoara, accusing: dysphagia for solids and liquids, deficit motor function, left hemiparesis and left facial paralysis, paleness of skin, fatigue, loss of appetite. Clinical examination on admission: the general conditions influenced, conscious; left facial paralysis, pallor; language deposits candidiasis, respiratory and cardiac- normal; digestive system: abdomen soft, movable breathing, painless, liver and spleen impalpable, urogenital apparatus: probe bladder; nervous system: no signs of meningeal irritation.

Results: Cranial CT scan showed lesions typical of cerebral toxoplasmosis. CD4 = 31 cells/ μ L; Viral load = 590381 copies/ml; WBC = 2930/ μ L, PLT = 325000/ μ L, HGB = 10.5 g/dl, CRP = 95.69 mg/l, FA = 71.8 U/L, VSH = 85 mm/h, Toxo IgG = 282 U/ML positive. The treatment was with Clindamycin 300 mg/fl, Daraprim 25 mg/tb, Mannitol 250 ml/fl, Fluconazole 200 mg/fl, Levetiracetam 500 mg/tb, Biseptol 480 mg, Dexamethasone f, Arnetin f and ARV therapy with AZT/Lamivudine cp + Norvir 100mg cp + Prezista 600 mg/cp. Evolution was unfavorable, the patient was cooperative difficult, with periods of unconsciousness, immovable, with dysphagia for solids and liquids.

Conclusions: Late detection of the disease AIDS collaborated with noncompliant patient treatment may encourage nerologice focal complications (cerebral toxoplasmosis) or non focal.

ACUTE LIVER FAILURE ASSOCIATED WITH ACUTE HEPATITIS B AND DRUG USE



ALEXANDRA ILIES, MONICA CIALMA, LOREDANA KISLINGHER, SORINA MITRESCU, MIRELA PALIU, DELIA NAN, DANIELA MIHALCEA, CAMELIA NIȚĂ, IOSIF MARINCU

Department of Infectious Diseases, University of Medicine and Pharmacy „Victor Babes” Timisoara

Objectives: a clinical case presentation with acute liver failure associated with virus hepatic B infection, detected in time of admission.

Patients and methods: The authors present the case of a 23 yers old patient with unknown hepatitis B virus, from Timisoara, Timis, urgently hospitalized in Hospital of Infectious Diseases Timisoara, with suspected acute hepatitis. 12 hours with acute onset, dark urine, painful on palpation abdomen, jaundice skin and mucous membranes. Clinical examination on admission: influenced general state, afebrile, skin and mucous jaundice, normal stetacustic cardiopulmonary relations, TA = 120/70 mmHg, AV = 64 b/min, slender abdomen, painful on palpation in the upper abdomen, nausea, vomiting, chairs alcoholic, liver 2-3 cm below the costal margin, spleen impalpable, free kidney lodges, dark urine, without signs of meningeal irritation. The patient was admission in the Hospital of Infectious Diseases Division I.

Results: WBC = 6690/mm³, HBs Ag reactive, alkaline phosphatase = 159,2 U/L, platelets = 120,000/mm³, TGP = 9745 U/L, TGO = 7286,2 U/L, BD = 5,8 mg/dl, G-GT = 147 5 U/ L, PT = 36.2 seconds, INR = 3.06, Ab HIV = negative. The treatment was with infusion solutions, antibiotics, anti-inflammatory, hepatoprotective, gastric antisecretory, but the patient's evolution was unfavorable.

Conclusions: Late detection of HBV infection during acute liver failure occurrence can contribute to the unfavorable sick in patients with drug use.

ACUTE MENINGITIS DUE TO LISTERIA MONOCYTOGENES WITH FAVORABLE EVOLUTION



IULIANA CARAMANGIU*, OVIDIU ROSCA, MONICA CIALMA**,
SORINA MITRESCU*, OANA SACEANU*, ANDREEA
ARDELEANU*, CAMELIA NIȚĂ, IOSIF MARINCU****

***Department of Infection Diseases I, “Victor Babes” Clinical Hospital of Infectious Diseases Timisoara**

****Department of Infection Diseases I, University of Medicine and Pharmacy “Victor Babes” Timisoara**

Objective: We intend to approach a clinical case of acute meningitis due to Listeria Monocytogenes, who presented a favorable evolution, despite the complications that occurred during hospitalization.

Methods: The authors present the case of a patient of 53 years, without pathological history, who was hospitalized in the Clinic of Infectious Diseases “Victor Babes” Hospital Timisoara. Symptoms started one day before admission, with malaise, fever, $T=37,5^{\circ}\text{C}$, intense headache, neck stiffness, disoriented temporo-spatially, conscious, respiratory and hemodynamic balanced, $AP=128/71$ mmHg, diuresis present on the bladder probe.

Results: On admission was performed a lumbar puncture, that revealed: CSF opalescence, normotensive, increased protein level, increased glucose level, increased pleocytosis. A brain CT was performed that was normal. When was received CSF culture results and blood culture, collected at admission, which revealed Listeria Monocytogenes we started treatment with Ampicillin and Gentamicin. On 03.03.2015 was performed MRI brain control which revealed hydrocephalus and decided to increase the dose of Mannitol. In 17.03.2015 cerebral CT was performed that revealed an improvement in control compared to previous MRI evaluation. During hospitalization were also performed 5 additional lumbar punctures, that have revealed an xantocrom appearance, increased RBC, increased pleocytosis, increased glucose level and increased protein level, but with a favorable evolution in the dynamics. The last lumbar puncture was in the normal range.

Conclusions: In contrast to other cases in the literature, we can say that, despite the severity of Listeria Monocytogenes meningitis and complications occurring during hospitalization, the patient's evolution was favorable, with remission of symptoms.

RECENT DIAGNOSED PULMONARY TUBERCULOSIS IN A PATIENT WITH STAGE C3 AIDS UNCOOPERATIVE



LOREDANA ELENA KISLINGHER, R. OPREANU, ALEXANDRA ILIES, L. VOCHITA, SORINA MITRESCU, VALERIA BICA, I. MARINCU

Department of Infectious Diseases, Pulmonary, Epidemiology and Parasitology, University of Medicine and Pharmacy, „Victor Babes” Timisoara

Objectives: presentation of a clinical case with stage C3 HIV infection in a patient recently diagnosed with pulmonary tuberculosis and opportunistic infections.

Material and Methods: The authors presents the case of a patient aged 29 years in 2010 found HIV a positive in urban areas Timis county of, which followed 4 months ARV treatment on his own initiative discontinued the medication up to 2015. In February 2015 is hospitalized Clinic for Infectious Diseases in Timisoara the patient having the general condition influenced by approximately 6 days this fever, chills, coughing up, diarrhea, dysphonia, dysphagia, inappetence. The clinical examination at admission: general status dehydrated impacted pale skin, herpes labialis, submandibular adenopathy, bilateral the hilarious tightened vesicular murmur, rales disseminated the whole area bronchial pulmonary, diffuse sensitive abdomen and palpation, without signs of meningeal irritation.

Results: CT examne show wound hipodensa 14/15mm with right parietal subcortical provision, MRI revealed right parietal subcortical lesion 1cm only aspect of edema cut unspecific postinfectious possible, HIV antibodies (Elisa) = pozitiv, Toxo IgM = 1.62 UI/ml positive, Blood culture = absence microbial growing, TGO = 284.5 U/L, ALT = 491.1, G-GT = 895 U/L, alkaline phosphatase = 1002 U/L, BD = 1.07 mg/dL, BT = 1.38 mg/dL, Ag HBs = negative; Chest radiography: zone nonhomogeneous opacification extensive process of condensation; Sputum exam = 80% Pseudomonas spp, 20% Candida, PCR = Mycobacterium tuberculosis, CD4=1 cells/ μ L, VL HV1-ARN = 878.000 copies/ml, VDRL = negative. Instituted antibiotics, antifungals, gastric antisecretory, hepatoprotectors, antiretrovirals, mucolytics, anti-tuberculosis, the hemodynamic rebalancing solutions, but the outcome was unfavorable.

Conclusions: Failure prescribed antiretroviral therapy for 5 years and etiology oportuniste infections, toxoplasmosis, candidiasis, pulmonary tuberculosis, lung disease Pseudomonas spp, low levels of CD4 (1 cells/ μ L) contributed to the unfavorable evolution of the patient.

BARTONELLA HENSELAE INFECTION WITH LYMPHATIC AND LYMPH NODAL SPREADING



IOSIF MARINCU, EMILIAN POPOVICI, PATRICIA POPTELECAN, OANA SĂCEANU, LOREDANA KISLINGHER, SORINA MITRESCU, ALEXANDRA ILIEȘ, CAMELIA NIȚĂ, SORINA LAITIN

Department of Infectious Diseases, Pulmonary, Epidemiology and Parasitology, University of Medicine and Pharmacy, „Victor Babes” Timisoara

Objectives: the presentation of a clinical case of interdigital infection with Bartonella henselae associated with unilateral axillary lymphadenopathy.

Patients and Methods: A 37 years old male patient, without known pathological medical history, came to the Clinic of Infectious Diseases after the appearance of a painful lymph node in the left arm pit. The physical examination on admission showed good general condition, fever (37.9 °C), the patient accused pain in the left arm pit radiating to the left forearm and arm; at the palpation of the left arm pit the physician detected a structure about 2/2cm, painful on palpation, mobile, the patient had also an infected interdigital wound (finger II-IV) at the left hand, made by scratching by his own cat; adipose tissue well represented; without any pathological changes concerning the respiratory, cardiovascular, digestive and urinary systems.

Results: WBC = 11390/mm³, PMN = 72%, ESR = 15 mm/h, Fibrinogen = 4.34 g/L, glycaemia = 94 mg/dL, serum Urea = 28.1 mg/dL, serum creatinine = 0.76 mg/dL, CRP = 3.67 mg/L, ASLO = <200 IU/ml, blood cultures = sterile, HBs Ag = negative, HCV Ab = negative, HIV Ab = negative, the culture of the interdigital wound secretion revealed the presence of the bacillus Bartonella henselae. After the cleansing of the wound with betadine and hydrogen peroxide, a sterile dressing was applied. Under treatment with ceftriaxone (2x2 g/day i.v. for 7 days), ibuprofen (2x200 mg/day), omeprazole (2x20 mg/day) the general status of the patient improved, he became afebrile in the 2nd day, the local pain is diminished, and the lymphadenopathy disappears at the end of therapy.

Conclusions: The early treatment of wounds produced by cat scratches using antibiotics and appropriate cleansing of the wounds can prevent the lymphatic dissemination of the infection affecting the lymph nodes or causing other complications.

SEVERE HEPATIC AND RENAL FAILURE TO AN IMMUNOCOMPROMISED PATIENT WITH ACUTE HEPATITIS A



**IOSIF MARINCU, EMILIAN POPOVICI, SORINA LAITIN,
PATRICIA POPTELECAN, BOGDAN TRINCĂ, LAURENȚIU
VOCHITA, MIRELAPALIU, DOGARU DELIA, LIVIUS ȚÎRNEA**

Department of Infectious Diseases, Pulmonary, Epidemiology and Parasitology, University of Medicine and Pharmacy, "Victor Babes" Timisoara

Objectives: the presentation of a clinical case of a patient with fatal hepatic and renal failure in an elderly patient, immunosuppressed with acute hepatitis A

Patients and methods: The authors present the case of a 79 years old patient who was admitted in the Clinic of Infectious Diseases with jaundice syndrome. On admission the patient accused severe asthenia, nausea, vomiting, loss of appetite, dizziness, liver pain, oliguria and itching skin. The physical examination showed bad general condition, afebrile, scleral and skin jaundice, persistent skin fold, diminished subcutaneous tissue, cachexia, dry lips, abdomen sensitive to deep palpation in the right upper quadrant, liver at 2-2.5-2 cm under the right costal margin, oliguria during the last 24 hours, but retained consciousness; rhythmic heart sounds, BP=110/65 mmHg, HR=95 beats/min.

Results: WBC = 11600/ μ L, PMN = 76.6%, PLT= 267000/ μ L, Hgb = 8.9 g/dL, ESR = 80 mm/1h, ALT = 237.7 U/L, AST = 160.9 U/L, BT = 19.23 mg/dL, BD = 12.3 mg/dL, G-GT = 119.1 U/L, AF = 244.1 U/L, serum urea = 330.6 mg/dL, serum creatinine = 6.82 mg/dL, serum C-reactive protein = 169.26 mg/L, serum total proteins = 3.98 g/dL, prothrombin time (PT) = 18.6 sec., prothrombin activity (APT%) = 49.2%, serum Cholinesterase = 2103 U/L, HAV IgM Ab = positive, HBc IgM Ab = negative, HCV Ab = negative, HBs Ag= negative. The treatment was complex with Glucose, Arginine-Sorbitol, Dexamethasone, Arnetin, Ampicillin, Mannitol, Furosemide, Aspatofort, Hepamertz, etc., but the outcome was unfavorable. In the 4th day of admittance the general condition of the patient alters, becomes uncooperative, appears anuria, hepatic foetor, metabolic acidosis, the hepatic encephalopathy installs and the patient dies.

Conclusions: Acute hepatitis A associated with an immunosuppressed system of an old woman with multiple comorbidities may progress to acute liver failure and death.

DISEMINATED CRYPTOCOCCOSIS IN HIV/AIDS MULTI-EXPERIENCED PATIENT



MIHALCEA DANIELA, MITRESCU SORINA, ROȘCA OVIDIU, ARDELEAN ANDREEA, POPTELECAN PATRICIA, ILIEȘ ALEXANDRA, SĂCEANU OANA, VALERIA BICA, IOSIF MARINCU

Department of Infectious Diseases, University of Medicine and Pharmacy „Victor Babes” Timisoara

Cryptococcosis is a deadly opportunistic infection caused by an encapsulated yeast, Cryptococcus neoformans. The major predisposing factor is the profound cellular immune defect caused by HIV infection.

Objectives: presentation of a clinical case of disseminated cryptococcosis and cryptococcal meningitis in HIV AIDS a C3 stage in a multi-experienced patient.

Methods: the authors present a patient with HIV infection stage C3, diagnosed in 2001, current orofaringiana candidiasis, chronic infection with toxoplasma, pleurisy TBC (2013), leukopenia with lymphopenia, HIV encephalopathy and is admitted in Infectious Diseases Hospital Timisoara for prolonged febrile syndrome, seizures, walked unsteadily and cough with expectoration, which occurred in January 2015. Objective exam at inpatient offer condition influenced, aware cooperative with the temperature 37 °C, 110/73 mm Hg blood pressure, pulse 113 beats/minute, bronchial pulmonary rales disseminated, mobile abdomen with breath, haematuria, no meningeal signs, walked unsteadily with wide base, unsystematic Romberg, left motor deficiency hemibody, live osteotendinous reflexes.

Results: Laboratory: WBC=1900/μL; HGB=7,7 g/dL; HCT=23,5%; LYMPH=15%; NEUT=59%; PLT=115000 μL, ESR=140 mm/h; lingual examination = candidiasis present, CD4=5 cells/μL, CD4/CD8=0,05 cells/μL, IgG Toxo=33-positive, VL=323867 copies/mL, hemocultures-Cryptococcus neoformans, CSF fungal examination-Cryptococcus neoformans. Thorax X-Ray - Dew process alveolar aspect in setting up. Without obvious lesions bacillare.

Established treatment with Fluconazole 1200 mg/day for 14 days then 400 mg/day for 60 days and then 200 mg/day for 1 year; antibiotics, anti-inflammatory drugs, antiretroviral therapy, cerebral, depleted, mucolytics administration with favorable evolution. After 7 days of antimycotic the patient releases normal temperatures.

Conclusions: Disseminated Cryptococcosis meningitis and cryptococica has a favorable evolution under the lengthy treatment with high doses of Fluconazole.

HEPATIC CIRRHOSIS HCV FROM A PATIENT DIAGNOSED WITH RENAL TRANSPLANTATION



MIRELA PALIU, M. CURESCU, B. CERBU, S. MITRESCU, O. SACEANU, DOGARU DELIA, I. MARINCU

Department of Infectious Diseases, Pulmonary, Epidemiology and Parasitology, University of Medicine and Pharmacy, "Victor Babes" Timisoara

Objectives: Case presentation of a HCV hepatic cirrhosis detected after numerous surgeries.

Material and methods: The authors present the case of a 33 year old patient who is known for suffering from HCV hepatic cirrhosis and a renal transplant; he is from an urban area, Timiscounty. Hospitalized in emergency in the infectious diseases clinic from Timisoara with suspected interstitial pneumonia. It began for about 3 days with fever, chills, weight loss, right upper quadrant pain, asthenia, fatigue, loss of appetite. His personal history shows that the patient was born with multiple defects. It is known that from the age of 2 he suffered from a ventricular septal defect and it was operated in the year 2000, with surgeries for the reimplantation of the left ureter (2003), in 2007 he was proposed for renal transplant having a living donor (the mother). Before the transplant he was diagnosed with HCV cirrhosis. Despite being diagnosed with vascular and parenchymal decompensated HCV cirrhosis of the liver, with contraindication to therapy with Interferon + Ribavirin, the renal transplant was performed. The clinical examination on admission: general state moderately influenced, fever 39 degrees C, abdomen soft, moving when breathing, spontaneous right upper quadrant pain also on palpation, TA= 130/75 mmHg, AV-85b / min, IMC=19,42kg/m².

Results: Chest radiography Drawing emphasized bilateral. Abdominal ultrasound: sized liver without ascites, contracted gallbladder without stones, unique kidney steatosis between cortical and medullary limit. WBC=1.190/μL, RBC=4090000/μL, PLT=163000/μL, BD=0,09 mg/dl, BT=0,41 mg/dl, GGT=107,2 U/L, AST=29,4 U/L, ALT=30,5 U/L, serum creatinine=3,56 mg/dl, creatinine clearance=22.54, triglycerides=135 mg/dl, serum urea=74,9 mg/dl, total protein in serum=6,82 g/dl, colinestereaza=7503 U/L, Hb=11 g/dl, NEUT=25%. The treatment was started with antibiotics, anti-inflammatory medicine, gastric antisecretory medication, antifungal, hepatoprotective and hydro-electrolyte rebalancing solutions. Favorable development with anti-fever medication within 24 hours without any complaints.

Conclusions: Late detection of hepatitis C that contributed to the unfavorable patient and immunosuppressive therapy. The patient was referred to the clinic AKH Vienna in antiviral therapy with Interferon Free Sofosbuvir + Ledipasvir (Harvoni for 12 weeks). The patient is excluded from the studio because there meets the criteria for inclusion: creatinine ≤ 2 mg/dl.

LIVER CANCER METASTASES IN A PATIENT WITH PROLONGED FEBRILE SYNDROME



CIALMA MONICA, ALEXANDRA ILIEȘ, OVIDIU ROSCA, OANA SĂCEANU, PATRICIA POPTELECAN, IULIA CARAMANGIU, ANDREEA ARDELEANU, IOSIF MARINCU

Department of Infectious Diseases, University of Medicine and Pharmacy „Victor Babes” Timisoara

Objectives: presentation of a clinical case with liver cancer with metastases detected at the time of admission

Patients and methods: The authors present a patient aged 44 years, unknown to hepatic carcinoma, Timisoara, hospitalized in the Clinic of Infectious Diseases prolonged febrile syndrome. Debut for 1 month with fever, chills, cough, weight loss over 10kg. Physical examination at admission: general state influenced feverishly $T = 39^{\circ}\text{C}$, pale skin and mucous membranes, stethacustic cardiopulmonary normal, BP: 117/53 mmHg, AV: 103 b/min, MV tightened, cough, abdominal palpation painless, liver rebord, spleen impalpable, renal lodges free, Giordano (-) bilateral physiological urination, without signs of irritation meningeal. We decided hospitalization in infectious disease clinic for tratamnet and special investigations.

Results: WBC = 15770/ μl , Hb = 10.2 g/dL, HT = 30.4%, alkaline phosphatase = 272.6 U/L, GGT = 145,7 U/L, AST = 48.4 U/L, ALT = 39,8 U/L, C-reactive protein = 244.91 mg/L, Escherichia coli present Urinalysis = 70000 CFU/ml. Liver ultrasound abdominal = inomogene structure with multiple images cockade require abdominal CT, VP = 9 mm, CBP = 3 mm, unviewed post prandial gallbladder, pancreas heterogeneous normoecogen, Kidney right = 104 / 46 mm, IP = 14 mm, transonic image, with its walls, left kidney = 106/57 mm, IP = 17 mm, spleen small amount of ascites perisplenic 111 mm, ascites in small amounts splenic portal Ax = 19 mm, ascites in Douglas. The treatment was with infusion solutions, Cefort (2x2 g/day), Dexamethasone, Bromhexim, Arnetin, evolution is stationary.

Conclusions: One of the causes of prolonged febrile syndrome can to be and hepatic metastatic neoplasm.

GROIN HERPES ZOSTER ASSOCIATED WITH RECENTLY DIAGNOSED WITH CHRONIC HEPATITIS HCV



OANA SACEANU*, D. MIHALCEA*, D. NAN*, P. POPTELECAN*,
A. ARDELEANU*, L. KISSLINGER*, D. DOGARU*, I. MARINCU*

*Department of Infectious Diseases, University of Medicine and Pharmacy „Victor Babes”
Timisoara

Objectives: the presentation of a clinical case with herpes zoster in an HCV-infected old patient.

Patients and methods: the authors present the case of a female patient, 85 years old, recently diagnosed with chronic hepatitis C, coming from rural settlement, Timis county, with recent surgical intervention for vesicular hidrops, hospitalized in the Clinic of Infectious Diseases for left lombo-groin herpes zoster. The symptoms begun a week ago with severe pain, fever and a unilateral vesicular dermatomal eruption. The clinical examination showed unilateral lesions at different stages of evolution, most of them crusting, with left lombo-groin dermatomal distribution; pulmonary and cardiac exams in normal parameters; abdominal exam shows a postsurgical scar with benign evolution, with no pain and abnormal findings; CNS exam without signs of meningeal irritation.

*Results: blood investigations in normal range WBC=9900/ μ l (Neutrophils =70%, Lymphocytes=19%, Monocytes=4,7%, Eosinophils=5,7%, Basophils=0,6%), RBC=4,2*10⁶/ μ l, Platelets=334000/ μ l, normal aminotransferase activity (AST=14,1 U/l; ALT=13,8 U/l), GGT=68,1 U/l, serum cholinesterase=7221 U/l, albumin=48,5%, α 1-gb=3,5%, α 2-gb=14,5%, ESR=20mm/h, CRP=5,42mg/l, AgHBs=negative, AcHCV=positive. The urine culture revealed Klebsiella pneumoniae \geq 100.000 UFC/ml sensible at Imipenem and Amikacin. The nasal exudate revealed Staphylococcus aureus \geq 10UFC. The patient was treated with Acyclovir 800mg five times/day, for 10 days, topical antipruritic substances, anti-inflammatory, urinary antiseptics, hepatoprotective medicines.*

Conclusion: reactivation of latent VZV in immunocompromised hosts (elderly HCV-infected woman with postsurgical status).

ERYSIPELAS OF THE UPPER LIMB AT A PATIENT WITH UNILATERAL MASTECTOMY



PATRICIA POPTELECAN*, O. ROSCA*, A. ARDELEANU*, I. CARAMANGIU*, O. SACEANU*, C. NIȚĂ, I. MARINCU*

***Department of Infectious Diseases, University of Medicine and Pharmacy „Victor Babes” Timisoara**

Objectives: the presentation of a clinical case with erysipelas in the right upper limb at a patient with unilateral mastectomy secondary to breast cancer.

Patients and methods: The authors present the case of a female patient, 70 years old, coming from the rural area in Timis county, with unilateral mastectomy in 2008, treated afterwards with chemo- and radiotherapy, first grade obesity (BMI=31.5 kg/m²), type 2 diabetes treated with oral agents, psoriasis, chronic hepatitis HBV, and hypertension. The patient is evaluated in the emergency room for fevers, chills, general illness and the appearance of an erythematous skin lesion with a sharply demarcated raised edge, with swelling and pain in the arm and right forearm and anterior and posterior upper chest, symptoms that began in the previous day. From the emergency room, the patient is referred to the Clinic of Infectious Diseases. The physical examination at admission showed: general illness, fever (39.6°C), with a red, swollen, warm, hardened and painful rash in the upper right limb (arm and forearm), axilla, anterior and posterior upper chest, and a chest scar secondary to the right mastectomy performed in 2008.

Results: blood culture didn't reveal any microbial growth, urine culture has detected mixed flora-40000 UFC/mL, WBC=11,310/μL with 81% neutrophils, erythrocyte=3,380,000/μL, hemoglobin=10.8g%, platelets=142,000/μL, CRP=296mg/L, ESR=80/1hour, TGP=36.8 U/L, TGO=50.5 U/L, total protein=5.8 g/dL. The treatment consisted in antibiotics (3rd generation cephalosporin, 2nd generation fluoroquinolone), anti-inflammatory, antipyretic, analgesic, gastric antisecretory and infusion solutions for hydration and electrolyte rebalancing. From the 2nd day of hospitalization the patient presented on the upper limb vesicles with clear liquid. Under the treatment, the general status of the patient was favorable, with the progressive remission of symptoms.

Conclusion: Taking into consideration the risk factors for this patient (right mastectomy, chemotherapy and radio-therapy, diabetes, psoriasis, obesity) for upper limb erysipelas, helps the physician to observe a population group at risk for this condition and requires targeted measures in order to control and prevent skin infections in these patients.

COAGULASE-NEGATIVE STAPHYLOCOCCAL SEPSIS ASSOCIATED WITH FATAL ACUTE RESPIRATORY AND HEPATIC FAILURE



DUMEA RAMONA, SORINA LAITIN, POPTELECAN PATRICIA, CAMELIA NITA, OANA SACEANU, ALEXANDRA ILIES, IOSIF MARINCU

*Department of Infectious Diseases, Pulmonary and Parasitology, University of Medicine and Pharmacy, „Victor Babes” Timisoara

Objectives: presentation of a clinical case of infection with coagulase-negative Staphylococcus, evolving to sepsis, respiratory and hepatic decompensation.

Patients and methods: The authors present the case of a patient aged 64, known with asthma and depressive anxiety disorder, urban, Caras-Severin, hospitalized in the Clinic of Infectious Diseases Timisoara, transfer from Hematology Department Resita Hospital, with Coagulase-negative Staphylococcal sepsis (positive blood culture) pulmonary starting point. From the recent history of patient we mention anemic syndrome, acute interstitial pneumonia for which the patient was hospitalized in the Department of Pneumology (03.2015), cystic formation right lung hilum (CT thorax 04.2015), hepatosplenomegaly unknown etiology, prolonged febrile syndrome. Clinical examination on admission: general state moderately influenced, pale skin and mucous, persistent skin fold, adipose tissue well represented, stethacoustic normal lung, tachycardia, BP = 90/60 mmHg, HR = 105 / min, distended abdomen volume by adipose panicle, painless, liver and spleen palpable below the costal margin.

Results: RBC (/mm³) = $2.4 \times 10^6 \rightarrow 3.22 \times 10^6$, HGB (g/dl) = 6.3 \rightarrow 8.9, PLT (/mm³) = 64.000 \rightarrow 16.000, ESR = 140 mm/h, ALT (U/L) = 7.9 \rightarrow 16.2, AST (U/L) = 7.5 \rightarrow 133.9, BT (mg/dL) = 0.97 \rightarrow 15.63, BD (mg/dL) = 0.77 \rightarrow 13.47, alkaline phosphatase (U/L) = 182.2 \rightarrow 359.5, GGT (U/L) = 140 \rightarrow 455.6, Cholinesterase (U/L) = 1090, urea (mg/dL) = 47.8 \rightarrow 141.3, creatinine (mg/dL) = 0.75 \rightarrow 1.6 \rightarrow 0.82, uric acid (mg/dL) = 8.06, total proteins (g/L) = 5.73, albumin = 32.8%, Procalcitonin (ng/mL) = 2.89, IgM HAV = non reactive, IgM HBc = non reactive, HBsAg = non-reactive, Ac HCV = non reactive, prothrombin time (sec) = 16.5 \rightarrow 27.6, Enterococcus spp urinalysis = 40,000 CFU / ml, exudate lingual = Present > 10 CFU Candida, blood culture = microbial growth absence. Native abdominal CT scan reveals hepato-splenomegaly, gallbladder containing hyperdense without dilatation of intrahepatic or extrahepatic biliary. The treatment was antibiotics (metronidazole + Tienam) as sensitivity testing, anti-inflammatory, antipyretic, gastroprotective, hepatoprotective, rebalancing electrolyte solutions, bronchodilators, probiotics, with favorable initial evolution febrile syndrome remission, but emphasizing anemic syndrome (Hb = 6.3 g/dL) and thrombocytopenia which were given 3 whole blood units, hemostatic and platelet. Subsequently, the patient decompensate with hepatic jaundice, biological detecting the cholestasis syndrome. It invalidates the suspicion of obstructive jaundice and suspicion of viral liver cirrhosis. The evolution is unfavorable, with occurrence of respiratory failure (SpO₂ = 86% O₂ mask). It was decided to transfer the patient to ICU section where oro-tracheal intubation is performed. Subsequently shows irremediable cardiac arrest.

Conclusions: septicemia staphylococcal coagulase-negative syndrome can cause cholestatic liver decompensation, with evolution to respiratory failure and death.

CUTANEOUS ANTHRAX IN A PATIENT WITH PROFESSIONAL RISK



SORINA MITRESCU, MIHALCEA DANIELA, NAN DELIA, ILIES ALEXANDRA, OANA SACEANU, PATRICIA POPTELECAN, ANDREEA ARDELEAN, PALIU MIRELA, IOSIF MARINCU

***Department of Infectious Diseases, University of Medicine and Pharmacy „Victor Babes” Timisoara**

*Anthrax is an acute disease caused by the bacterium *Bacillus anthracis*. Most forms of the disease are lethal, and it affects mostly animals. It is not contagious but can be transmitted through contact or consumption of infected meat. Effective vaccines against anthrax are available, and some forms of the disease respond well to antibiotic treatment. Anthrax commonly infects wild and domesticated herbivorous mammals that ingest or inhale the spores while grazing.*

Objectives: Presenting a case of anthrax in a patient practicing as a veterinary technician.

Patients and Methods: The authors present a case of anthrax, in a patient without some pathological antecedents which is practicing as veterinary technician which it made it's debut 2 weeks before admission as a rash of skin. In the evolution of eruptive skin elements first became erythematous papules and pustules with black crust formation in the central region and perilezional edema. Objective examination at admission offers: Condition satisfying, cooperative, temperature 37,2 °C, 103/73 blood pressure mmHg, pulse 113 beats/minute, cardiopulmonary balanced, mobile abdomen with breath, no meningeal signs. At the level of the proximal phalanx right index shows a 2 cm diameter lesion made up of central area of 0,5 cm with black crust surrounded by blistering and edema of wrist.

*Results: Laboratory: WBC=7700/ μ L; HGB=15,8 g/dL; HCT=45,5%; LYMPH=33,9%; NEUT=60%; PLT=216000 μ L, CRP=1,42 mg/L; wound secretion culture: *Bacillus anthracis* positive. Established treatment with: Penicillin G, 4 million to 6 hours, for fourteen days, anti-inflammatory drugs, antithermics, gastric antisecretory, with favorable evolution of general state and skin elements.*

Conclusions: Epidemiological data- veterinary technician, clinical data- papules and pustules with black crust formation in the central region and perilezional edema and therapeutics, they have contributed to the diagnosis of Cutaneous Anthrax.

CHRONIC HEPATITIS B VIRUS DETECTED IN AG HBS SEROCONVERSION DURING AN IMMUNOCOMPROMISED PATIENTS



VOCHITA LAURENTIU, OPREANU RADU, KISLINGHER
LOREDANA, TRINCA BOGDAN, POPTELECAN PATRICIA,
VALERIA BICA, CAMELIA NIȚĂ, MARINCU IOSIF

***Department of Infectious Diseases, University of Medicine and Pharmacy,,Victor Babes”
Timisoara**

Objectives: The presentation of a clinical case with NonHodgking lymphoma under chemotherapy and the exacerbations of chronic hepatitis B virus, with a seroconversion detected during an appearance at satellite cholecystitis.

Patients and methods: Patients aged 45 years known with NonHodgking lymphoma, chronic hepatitis B virus, to hospital emergency boarding Infectious Clinic Diseases in Timisoara with suspected acute hepatitis. Symptoms debut four days ago manifested by malaise, fever, vomiting, myalgia, abdominal pain, dark urine and jaundice intense sclero - skin. At clinical examination: general state influenced, febrile ($T=38.2^{\circ}\text{C}$), slightly dehydrated skin and mucous membranes and intense jaundice, respiratory system and cardio-vascular in normal parameters, TA = 110/65 mmHg, HR = 90 b/pm; on the superficial and deep palpation, the abdomen was painful in the right upper quadrant with hepatomegaly and with the presence of diuresis; conscious, cooperative, meningeal irritation unsigned.

Results: CT 4 regions (cervical, thoracic, abdomen, pelvis) left axillary biopsy that establish the diagnosis of diffuse T-cell lymphoma Nonhodgking stage IV B with severe pulmonary, AgHBs- positive, performed at the clinical of hematology. Abdominal- ultrasound reveals hepatomegaly, gallbladder with thickened walls, AgHBs - positive, Ac HBs- 327 index, TGO- 1091 U/L, TGP- 3550 U/L, GGT- 151.4 U/L, FA-243.9 U/L, BT-9.97 mg/dl, BD-8.62 mg/dl, Ag HBs- equivocal, after 7 days - negative, CRP-70 mg/L. It was established the antibiotic therapy, gastric antisecretory, liver supplement, rebalancing electrolyte solutions, with an favorable evolution of the patient.

Conclusions: The detection of Ag HBs seroconversion period with the appearance of a satellite cholecystitis at a patient with chronic hepatitis B and Nonhodgking lymphoma.

THE INFECTIOUS PATHOLOGY OF THE ELDERLY IN THE EXPERIENCE OF THE CLINIC OF INFECTIOUS DISEASES I TG. MUREȘ



**ZAHARIA-KÉZDI ERZSÉBET IRINGÓ*, CARMEN CHIRIAC*,
BRÎNDUȘA ȚILEA*, ANCA GEORGESCU*, CRISTINA
GÎRBOVAN*, EMESE PÁLFI****

***UMPh Tg Mureș, Mureș County Hospital, Infectious Diseases Clinic I, Tg Mureș,**

*** UMPh Tg Mureș**

Objects: The character of infectious diseases is continuously changing due to socio-economic conditions, the introduction of vaccinations and the growth of the immunosuppressed population. The elderly are considered to be physiologically immunosuppressed. In Romania we observe the annual growth of the population over 65. The purpose of our study was the evaluation of infectious pathology of the elderly patients under our care.

Materials and method: retrospective cross sectional study performed at the Cl. I. D. I Tg. Mures, on a group of 250 patients over 65 years of age admitted in the year 2014. We tracked demographic data, the principal diagnostics, associated diseases and evolution depending on sex and age groups.

Results: Of the 1571 patients hospitalized in this period, over 250 were over 65 years of age (26% over 80, median 74, maximum 94), 140 female, 134 from urban environment; average length of hospitalization 9.8 days (min. 1, max. 32), 34% admitted through the services of the emergency units. Main causes for hospitalization: pneumonia (80), cutaneous infections (53), pseudomembranous colitis with clostridium difficile (25), sepsis (18), Herpes zoster (17) and others. Most frequent associated illnesses: cardiovascular diseases (195), diabetes (58). Over 90% had over 5 comorbidities. The therapy of infectious diseases was also chosen depending on the interactions with chronic medication and other chronic diseases. 9 patients have deceased. We have observed no difference stemming from sex or age groups.

Conclusions: The most frequent illnesses for this category of patients are respiratory infections and cutaneous infections. The most frequent associated illness is cardiovascular disease. The evolution was favorable in over 96% of the cases as far as the infectious disease is concerned.

Key words: infectious, pathology, elderly

THE INFLUENCE OF ANTIVIRAL THERAPY ON LIVER FIBROSIS IN HEPATITIS PATIENTS WITH HCV



S. LAZAR**, **DANA OBRETIN***, **ADRIANA MOTOC***, **AUGUSTINA CULINESCU***, **E. CEAUSU****, **NICOLETA MINDU***, **DIANA COSTACHE***

***Hospital of Infectious Diseases "Dr Victor Babes", Bucharest**

**** University of Medicine and Pharmacy "Carol Davila" Bucharest**

Introduction: In Romania, the prevalence of HCV infection is 5.6% of the population. Chronic hepatitis C produce over time, liver fibrosis, and in 10-20% of cases the evolution is toward cirrhosis and hepatocellular carcinoma.

The severity of liver damage does not depend on the level of viral replication and viral genotype involved; it can be evaluated by METAVIR classification comprising a fibrosis score (F0-F4) and a score of necrotic inflammatory activity (A0- A3) either determined by liver biopsy, serum or by dosing biochemical markers (FibroTest).

Objectives: To determine the histological aspects and associated factors to significant or severe fibrosis in patients with chronic viral hepatitis C treated with antiviral therapy.

Methodes: retrospective study on 712 patients with chronic HCV treated in hospital of Infectious Diseases 'Dr Victor Babes' Bucharest, during 2007-2014.

Results: We treated 238 men and 474 women, of which 38% were aged between 51 and 60 years. The majority of the patients were treated with peg-IFN and Ribavirine and some with triple antiviral therapy (peg-IFN, Ribavirine, Boceprevir/ Telaprevir) and interferon-free molecules in studies. At the start of the treatment 49% patients had severe fibrosis(F3) and viral-load was > 600.000UI/ml in 53% cases. There were no significant differences between the levels of fibrosis at the moment of the diagnose between the patients with viral load <600.000 UI/ml vs patients with viral load> 600.000UI/ml. After 4 weeks of treatment from 165 patients investigated, 57 patients had undetectable viremia. 59% cases had undetectable viremia after 12 weeks of treatment and we obtained sustained virologic response in 50% of cases. From the patients with SVR positive, in 83% of cases the fibrosis decreased for the patients with RNA-HCV < 600.000UI/ml at the moment of the diagnose and in 73% of the cases with RNA-HCV >600.000UI/ml at the beginning. On the other side we didn't find significant improvements for the fibrosis regarding the patients who didn't obtain sustained virologic response, in most cases fibrosis remained unmodified or increased.

Conclusions: The rate of the sustained virologic response was satisfactory (50%). Fibrosis decreased in most of the cases with SVR positive, but fibrosis remained unmodified or increased in patients with no virological response. The treatment or the viral load<600.000 UI/ml didn't influence the fibrosis in cases with SVR negative.

BIOMARKERS- VALUABLE TOOLS IN DEFINING HCV SYSTEMIC INVOLVEMENT



SINZIANA DAIA*, ANCA STREINU-CERCEL, OANA SANDULESCU**, DANIELA OPRIS*, MT DAIA***, RUXANDRA IONESCU*, A. STREINU-CERCEL****

***Internal Medicine and Rheumatology, Sf. Maria Clinical Hospital, “Carol Davila” University of Medicine and Pharmacy, Bucharest**

****National Institute for Infectious Diseases "Prof. Dr. Matei Bals", “Carol Davila” University of Medicine and Pharmacy, Bucharest**

*****Obstetrics and Gynaecology, “Filantropia” Clinical Hospital, Bucharest**

Objective: The aim of the study is to evaluate the immunological differences between virus-associated rheumatic complaints and franc rheumatic diseases in HCV chronic infected patients.

Material and Methods: A descriptive, cross-sectional analysis of patients with HCV infection and rheumatic complaints was performed in two centers, a Rheumatology and an Infectious Diseases Center. Clinico-serological and virological work-up has been performed, in patients with HCV and arthritis, myalgia or sicca in terms of specific antibodies, rheumatoid factor, complement values, systemic inflammation (ESRmm/h, CRPmg/dl). The IL28B genotype was also performed in some of the patients. We used SPSS-Statistics22.

Results: The study group included a total of 85 patients, 71(83.5%) female and 11 (14.4%) male patients with the median age 58.±/10.2 years. Patients were stratified by rheumatic complaints: arthralgia/arthritis, sicca, myalgia. In the arthralgia/arthritis group, the main differences in immunologic features were the predominance 33% of anti-citrullinated protein antibodies (ACPA) and in higher titers (20.9(0-2673)) as compared to 0(0-1.4) and of rheumatoid factor (RF) in 72% patients, in higher titers (78.4(1-214.3)) as compared to 2.8(0-20) in the rheumatoid arthritis(RA)-group and HCV-arthritis respectively, with significant statistic value ($p<0.001$). There was a significant difference in CRP ($p=0.034$) and ESR ($p=0.037$) with higher values in the RA-group. Cryoglobulins were encountered in 4 (4.7%) patients, of which in 2 (2.3%) in association with sicca, low complement and positive FR. In patients with sicca, 12 (14.1%) had only the extrahepatic phenomena, while 2(2.3%) were ANA (antiRo antibodies) positive. As for myalgia, 11(12.9%) patients had the HCV-associated feature, while 2(2.3%) patients with significant systemic inflammation (median CRP=5XN value) had polymyalgia. The IL28B genotype frequencies in a subgroup were: 10 (39.2%) CC, 5(17.8%) TT and 14 (50%) CT.

Conclusion: Clinico-serological and virological work-up is mandatory in patients presenting with HCV and rheumatic complaints. anti-citrullinated protein antibodies anti-citrullinated protein antibodies, ANA /anti SS-A and antiSS-B antibodies, complement, cryoglobulins are important immunological features for the correct differential diagnosis.

Keywords: hepatitis C, extrahepatic, autoimmunity, biomarkers, anti-citrullinated protein antibodies, anti-citrullinated protein antibodies.