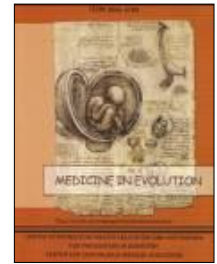


THE DISJUNCTOR, INDISPENSABLE TOOL DURING INSUFFICIENT TRANSVERSAL DEVELOPMENT OF THE UPPER JAW AND TREATMENT OF SEVERAL DENTO-MAXILLARY CROWDING ANOMALIES



M. ONEȚ¹, O. GRIVU¹, A. C. PODARIU², R. A. POPOVICI²,
R. SAVA ROȘIANU², R. OANCEA²

1. University of Medicine „Vasile Goldiș” Arad

2. University of Medicine and Pharmacy „Victor Babeș” Timișoara

ABSTRACT

Disjunction is the only method for skeletal enlargement of the upper jaw with insufficient transversal development (narrow jaw), strongly correlated with single or bilateral cross bite. The disjunctor acts on the median suture favoring the anterior positioning of the upper jaw in cases of a narrow, retrograde maxillary bone.

Sometimes, correlated to the patient's age, disjunction should be surgically assisted. It supposes very good anchorage; anchoring teeth should be fully erupted with fully developed roots (closed anatomical apex). In other circumstances, the disjunctor is not indicated and it is better to use transpalatal distractors.

Disjunction can cause root resorption, torque, extrusions or piercing of the vestibular table. In most cases, premolar extraction can be avoided.

Keywords: *Disjuncture, narrow jaw, transversal circumlocution, effects of the disjunctor, advantages for the patient*

Correspondence to:

Adrian Țandără

Adress: UMF "Carol Davila" Istriei str. No.4 bl. 21E et. 5 ap. 32 sect. 3 Bucharest, 031945

Phone: +40745178579

E-mail: adriantandara@yahoo.com

INTRODUCTION

Angell, E.C. describes the disjunction for the first time in in 1860, as an opening of the medio-sagital suture and the appearance of a space in the palatal suture, but there were so many side effects, that the appliance of such a device had limited indications ^{1, 2, 5}.

Today, the disjunctor is used for primary skeletal expansion of the upper jaw, inducing osteogenesis and histogenesis. Dilated airways become more permeable and the little patient gets used to nasal breathing which was difficult before. At the same time, the effect is exercised on all sutures and, this way, the upper jaw can be anteriorly tracted when a III-class anomaly is detected in early childhood ^{4, 6, 9}.

An age limit for the application of the disjunctor is not firmly established. In literature, the maximum age for the application of the disjunctor is set at 18 years but if the patient is already an adult; the application of the disjunctor should be surgically assisted. Unfortunately, the surgical procedure has no effects on the sutures of the middle third of the face. The classic disjunctors anchorage is preferred to be done on temporary teeth, to avoid root resorption of permanent teeth ^{3, 10}.

The disjunctor is composed of 4 rings welded through bars with a transversal screw and is usually luted on the first upper molars, the first premolars or first deciduous molars.

MATERIALS AND METHODS

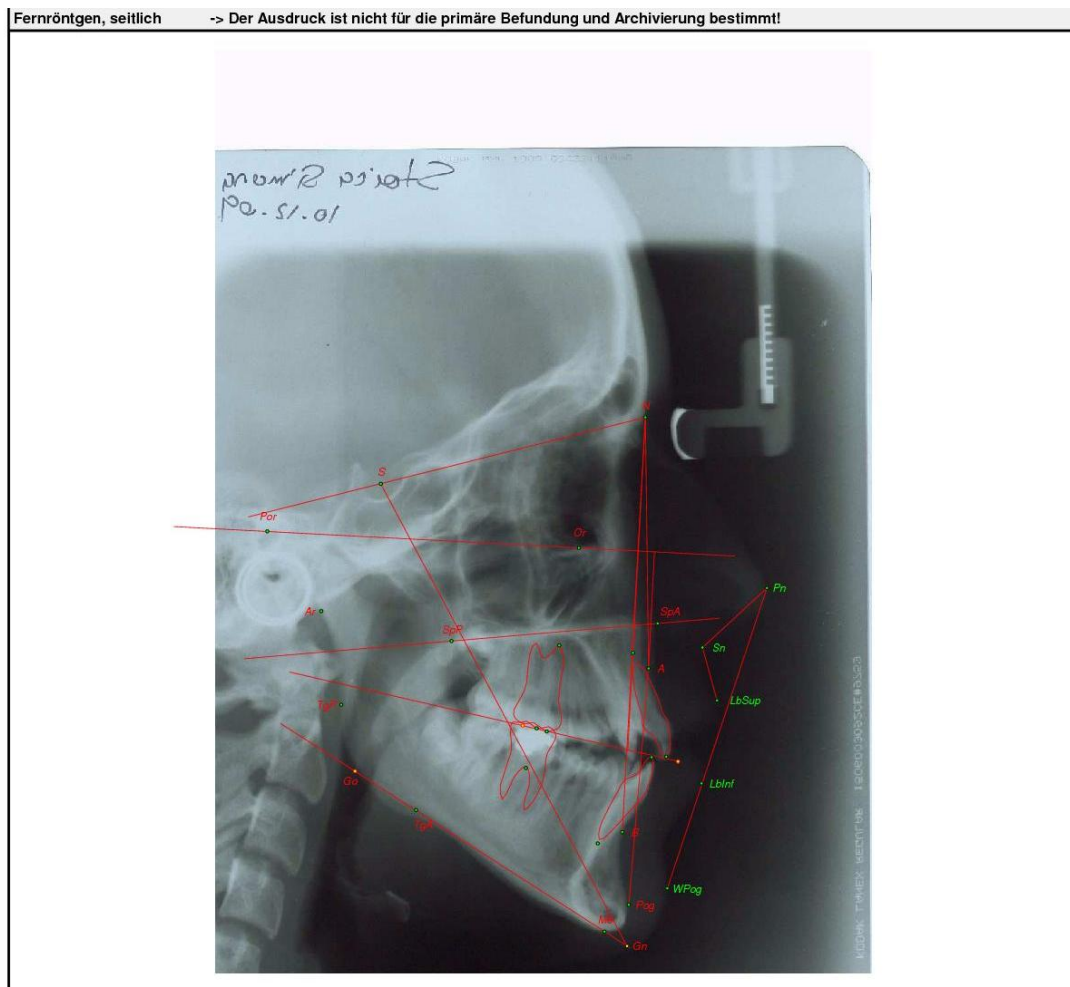A 14 years old patient addressed the orthodontic practice with a narrow jaw, dento-alveolar incongruence, crowding and bilateral cross bite. Existing space for the eruption of 1.3 and 2.3

showed 3 mm deficit for 1.3 and 4 mm for 2.3. Approximation on the model was correlated with cephalometric data:

The cefalometric analysis shows:

| Z1-WinCeph 5.0 | | Dr. Melinda Ana Onet (342234) | | Seite 1 von 2 | |
|---|----------------------------|-------------------------------|--------------------|---------------|--|
| PatNr. | : 18 | | | | |
| Name | : Stoica, Simona | | | | |
| Geschlecht | : w, kaukasisch | | | | |
| Geboren am | : 29.10.1994 (15 J + 5 M) | | | | |
| Datum | : 16.04.2010 | | | | |
| Behandler | : Dr. Onet Melinda | | | | |
| Gedruckt am | : Sa, 09.04.2011, 21:36:58 | | | | |
| Analyse: «MacGan» - MacGan-Analyse | | | | | |
| Parameter | Norm | Messwert | Kommentar / Befund | | |
| Pal-Mand | 28.5 ± 4.5 | 37.6 ° | offen | | |
| FMA-Mand | 23.0 ± 5.0 | 29.7 ° | offen | | |
| SGn-FMA | 59.5 ± 2.5 | 58.9 ° | | | |
| A-N | 1.0 ± 2.0 | 4.2 mm | prognath | | |
| SNA | 79.5 ± 3.5 | 76.6 ° | | | |
| N-Pog | -7.0 ± 3.0 | 2.4 mm | progen | | |
| SNB | 79.0 ± 4.0 | 72.8 ° | retrogen | | |
| ANB | 3.0 ± 1.5 | 3.9 ° | Skel. Klasse I | | |
| Wits | 0.0 ± 1.0 | -3.0 mm | Klasse III | | |
| 1OK-1UK | 127.5 ± 2.5 | 130.2 ° | | | |
| 1UK-ME | 93.5 ± 4.5 | 89.3 ° | | | |
| 1UK-NB | 3.5 ± 2.5 | 6.4 mm | protrudiert | | |
| 1UK-APog | 2.0 ± 2.0 | 2.7 mm | | | |
| 1OK-SN | 102.5 ± 3.5 | 93.6 ° | retroklin. | | |
| 1OK-APog | 4.5 ± 2.5 | 6.4 mm | | | |
| 1OK-A-FMA | 4.0 ± 2.0 | -5.7 mm | retrudiert | | |
| SnW | 100.0 ± 10.0 | 117.3 ° | | | |
| LbSup-ELinie | 1.5 ± 2.5 | -3.1 mm | hinter | | |
| LbInf-ELinie | 1.5 ± 2.5 | -0.1 mm | | | |

Lineare Werte berechnet für Fokus-Filmdist.: Int. cm / V = 1.000



We have discussed with the patient and made her aware of the importance of collaboration and personal support. Having her oral and written consent, we applied the brackets and then the disjunctor.

A 0.14 wire was applied. The patient daily activated the disjunctor by a 180° rotation and came every 4 weeks to a regular check-up, when wires were changed.

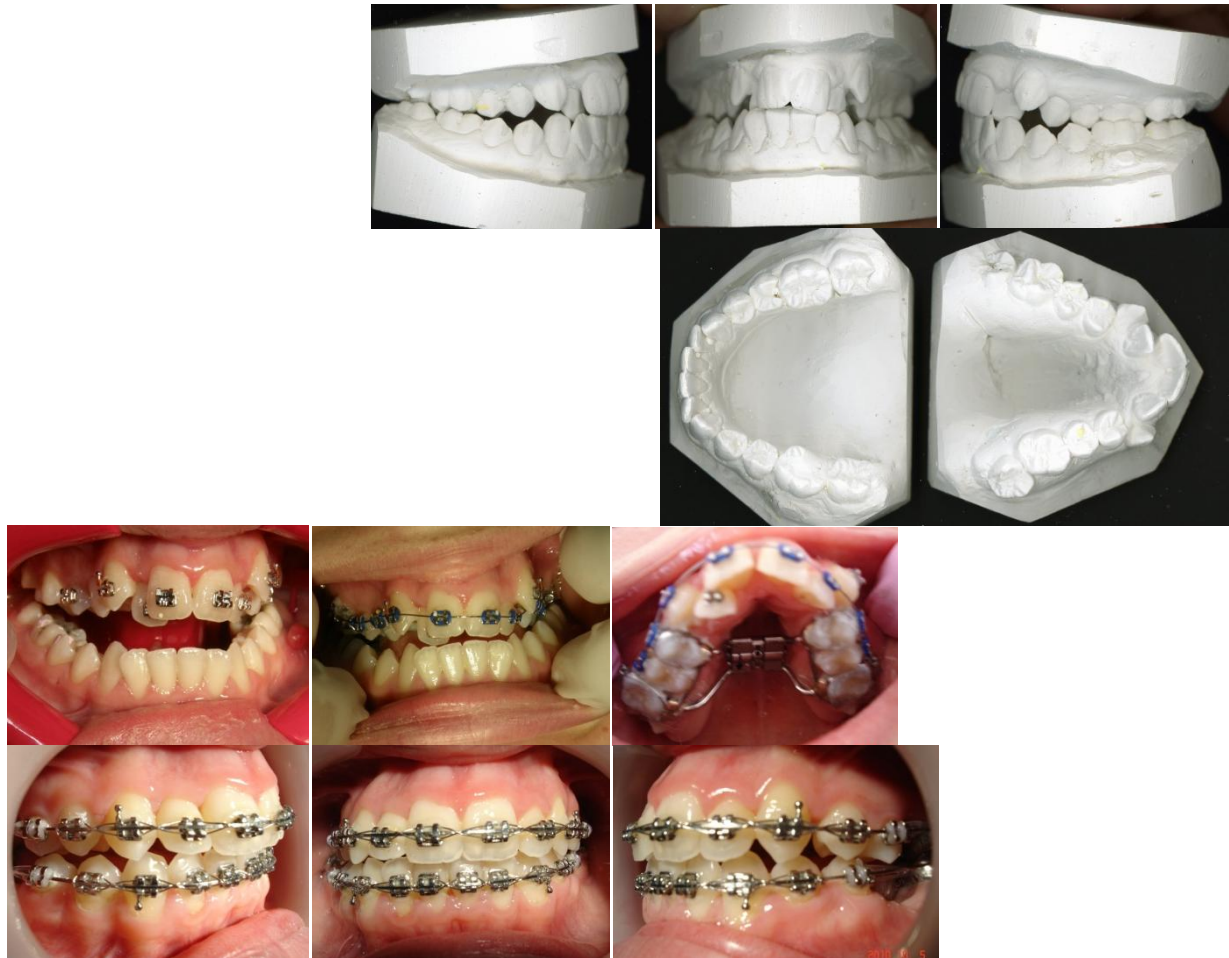
After 24 days we observed that there wasn't enough space for the alignment of the ectopic teeth and resolving the bilateral cross bite. The removal of the disjunctor was imposed, and three hours later a new one was applied. This one was assessed after 28 days of activation under the same conditions as

the first one. The screw of the disjunctor was then blocked. A period of 4 months followed, getting to a 19/25 wire.

These results permitted to continue the treatment: the second disjunctor was removed and 1.6, 2.6, 3.6, 4.6 were extracted over a period of 10 days, continuing with the 19/25 wire. After the expansion of the upper jaw, an open bite was present and the extraction of the 4 molars permitted us to obtain a functional occlusion.

A morphofunctional balancing phase follows.

As a follow-up of this paper, I will present other cases of transversal deficit, resolved by using the disjunctor. Each case is individualized.



RESULTS

After the use of the two medium disjunctors (with an opening of 9 mm), daily activated at 180° for 52 days along with brackets, we obtained sufficient expansion for the upper jaw to circumscribe the lower jaw respecting the three plans: transversal, sagittal, vertical.

After wearing the second disjunctor, there follows a contention period of minimum 4 months and then further orthodontic treatment is carried out un-

til optimal results are obtained. Through this kind of treatment we have obtained:

- Expansion of the upper jaw, permitting through fixed orthodontic appliances: alignment of ectopic canines (without the extraction of the first premolars)
- Open bite which was functionalized through the extraction of the 4 first permanent molars.

DISCUSSION

Using the two disjunctors for the 14 years old patient, over a period of 52 days, followed by 4 months of conten-

tion, allowed finishing the case without orthognatic surgery.

After wearing the second disjunctor, a 4 months contention period is absolutely necessary, to prevent partial relapse of the disjunction^{7,8}.

Unwanted side effects can appear if the disjunctor is not properly designed (by the dental technician), correctly applied (by the orthodontist) and properly activated (by the patient). The following side effects are recalled in li-

terature: vestibular torque or extrusion of the teeth used as anchorage, piercing of the alveolar bone or root resorption¹¹. None of those happened in our patient. It is well known that transpalatal distractors do not need anchorage on dental units, don't have any side effects and the treatment length is much shorter, but they require general anesthesia and a laborious application¹⁰.

REFERENCES

1. Angell EC. Treatment of irregularity of the permanent or adult teeth. *Dent Cosmos* 1860; 1:540-544,599-600.
2. Bell RA, Le Compte EJ. The effects of maxillary expansion using a quadhelix appliance during deciduous and mixed dentitions. *Am J Orthod* 1981; 79:152-161.
3. Davidovitch M, Efstthioub S, Sarnea O, Vardimon AD. Skeletal and dental response to rapid maxillary expansion with 2 versus 4 band appliances. *Am J Orthod Dentofacial Orthop* 2005; 127:483-492.
4. Derichsweiler H. Gaumennahterweiterung. Methode, Indikation und klinische Bedeutung. Munchen: Hanser 1956.
5. Frank SW, Engel GA. The effects of maxillary quadhelix appliance expansion on cephalometric measurements in growing orthodontic patients. *Am J Orthod* 1982; 81:378-389.
6. Glavan F. *Ortodontie si Ortopedie Dento-Faciala*. Editura Eubeea 2008
7. Haas AJ. Long term post-treatment evaluation of rapid palatal expansion. *Angle Orthod* 1980; 50:189-217.
8. Hayes JL. Rapid maxillary expansion. *Am J Orthod Dentofacial Orthop* 2006; 130:432-433.
9. Kunkel M, Ekert O, Wagner W. Veranderungen des nasalen Atemwegs durch transversal
10. Distraction des Oberkiefers. *Mund Kiefer Gesichtschir* 1999; 3:12-16.
11. Langford SR, Sims MR. Root surface resorption, repair and periodontal attachment following rapid maxillary expansion in man. *Am J Orthod* 1982; 81:108-115.