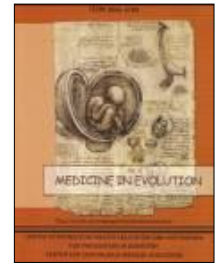


# EVALUATION OF ALAR BASE IN PATIENTS WITH SURGICAL MAXILLARY EXPANSION AND LE FORT I OSTEOTOMY

---



**BITA R.<sup>1</sup>, URTILA F.<sup>2</sup>, BRAD S.<sup>1</sup>, CRISAN R.<sup>3</sup>, CRISAN A.<sup>3</sup>,  
BALAN R.<sup>4</sup>, OGODESCU A.<sup>4</sup>, RIVIS M.<sup>2</sup>, TALPOS S.<sup>2</sup>**

1. Department of General and Dental Medical Radiology and Imaging, University of Medicine and Pharmacy „Victor Babeş” Timișoara, Romania.
2. Department of Cranio-Maxillo-Facial Surgery, University of Medicine and Pharmacy „Victor Babeş” Timișoara, Romania.
3. Private practice - Smile Clinic Timișoara, Romania - orthodontists.
4. Department of orthodontics, University of Medicine and Pharmacy „Victor Babeş” Timișoara, Romania.

## ABSTRACT

The *aim* of the study is to present the modifications that occur at the alar base in patients that had orthognathic surgical procedures in order to perform maxillary expansion or advancement.

15 patients were measured using the same methods of measurement. Intraoperative suture of the alar base was performed, using cinch suture or V-Y technique. These measurements were effectuated preoperative and 2, 6, and 12 month postoperative.

The *results* gathered showed a significant growth of the alar base in the postoperative period.

The *conclusions* present the growth in dimension of the alar base, even if suture was performed intraoperative. Though, the clinical and subjective result has not been compromised; we obtained satisfactory esthetic effects.

*Key terms:* Maxillary advancements, maxillary expansion, alar base, Le Fort I osteotomy.

Correspondence to:

Bită Romina

Faculty of Medicine and Pharmacy "V. Babeș" Eftimie Murgu nr 2, Timisoara, ROMANIA

e-mail adress: rominabita@yahoo.com

## INTRODUCTION

Orthognathic surgery is used in order to correct anomalies in maxilo-mandibular relationships, so it cans perform significant modifications of the facial appearance of the patients who have suffered this type of surgical procedures <sup>1, 2</sup>. These changes are linked directly to the magnitude of bone modifications needed to be performed and affect the hard tissue as well as the soft tissue. The maxillary deficiencies, in sagittal and transversal plan, are treated using surgical assisted maxillary expansion (Same) or surgical assisted rapid palatal expansion (Sarpe).<sup>1</sup> The transversal maxillary deficiencies are characterized by ogival palate, uni / bilateral crossbite, dental crowding.<sup>1</sup>

The sagital deficiencies show concave facial profile, dental crowding, narrow alar base, retrusive upper lip and lack of dental display as well as maxillary proclined incisors. Noticeable effects observed after Same/Sarpe are the increase of the nasal cavity volume

that guides to a better respiration and the growth of the transversal diameter of the upper jaw <sup>1, 2, 3, 4</sup>. We consider that the modification of the position of the lateral nasal walls leads to the improving of the internal nasal space. This appears after the surgical maxillary expansion.<sup>1</sup>

The nasal cavity is divided by the osteocartilaginous septum. The nasal skeleton, with the bony portion is limited antero-superior by the perpendicular lamina of the ethmoid bone, supero-posterior and inferior by the vomer<sup>2</sup>. It is linked with the upper jaw by the nasal crests.

The expectation after LeFort I osteotomy is to receive esthetic modifications at the nasal and labial level.<sup>2</sup> The surgical techniques used in time had as a goal to minimize decreasing of the volume of the upper lip, loss of vermillion, massive nasal enlargement. These modifications have little predictability.<sup>2</sup>

## AIM AND OBJECTIVE

From the SAME techniques, we chose the incomplete Le Fort I osteotomy, associated with the osteotomy of the palatine raphe and periodic activation of the expander put in position to separate the maxilla. We used the cla-

ssic LeFort I osteotomy with no other modifications. These procedures modify the alar base.

The aim of this study is to analyze the alar base in patients undergoing Same or Sarpe.

## MATERIAL AND METHODE

15 patients, with palatine deficiencies, transversal or sagital participated in this analysis. Minimum of age was 19 years and oldest 36. These patients had never before undergone orthodontic treatment. They presented no general diseases.

The patients were all measured and treated by the same surgical team, u-

sing a caliper positioned on the lateral surfaces of the alar insertions.

Surgically, we performed Le Fort I osteotomies or incomplete LeFort I osteotomies, without the osteotomy of the nasal septum. The expander used in these patients had dento-supported type. We preceded in all cases the internal suture of the alar base, measuring

and keeping the data obtained preoperative. We also supplemented by using

the V-Y technique where needed.

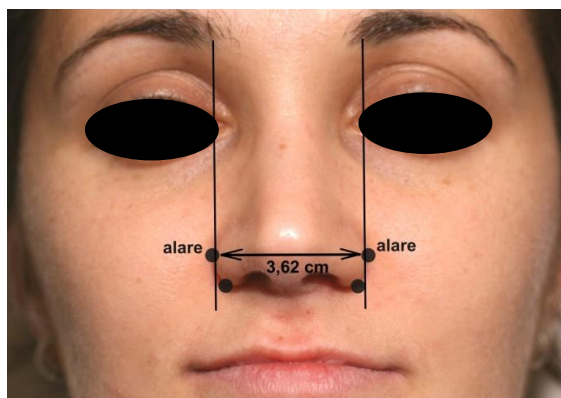


Fig. 1 The nasal alar width measured on the patient.

The expander is placed in position 5-7 days after the surgical intervention and it is being activated periodically to the moment of the complete annulations of the cross bites. Next an acrylic retainer is positioned; in order to stabilize the obtained results. After 4-6 months the conventional orthodontic treatment can be resumed, according to the

well known therapy orthodontic treatment-orthognathic surgery-orthodontic treatment.

The alar bases were measured 2, 6 and 12 months after the surgical procedure. The distances between the most lateral points of each alar contour have been held as reference points at each measurement.

## RESULTS

15 patients have been analyzed. Medium age was 24, 6. 12 patients are female and 3 are male. Pre-surgically, the lowest alar base value was 25 mm

and the highest was 34 mm. After the surgical procedure, the lowest value found was 28 and the highest was 36, 5 mm.

## DISCUSSIONS

The analyzed patients suffered maxillary advancements using Le Fort I technique, complete and incomplete and cinch suture to the alar base level. The incomplete Le fort I osteotomy was followed by the placement and periodic activation of a dental-supported expander over a period of maximum 4 months postoperatively. All the patients presented skeletal maturity and the

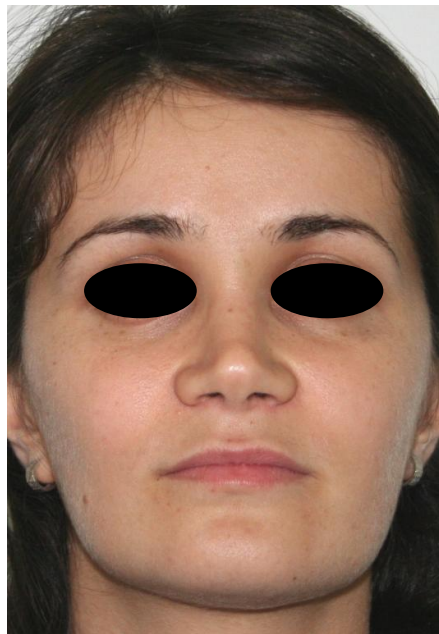surgical techniques used showed good stability and results.

The aim of this complex treatment is to increase the dimension of the upper jaw by using a combined orthodontic and surgical approach. The intervention reflects itself on skeletal level, dental level as well on the nasal cavity level. These conditions led to the raising of the nasal volume and of the internal nasal space. By inducing ske-

letal modifications it is expected to obtain modifications of the covering soft tissues, especially the nose and the upper lip. The surgical techniques that were chosen, Le Fort I maxillary advancements and incomplete Le Fort I, with incision and dissection from the first upper molar to the controlateral upper molar, with osteotomy from the piri-

form aperture to the pterygomaxillary joint and the disjunction of the upper jaw are considered invasive interventions.

They may lead to altering of the alar base due to the decollation of the soft tissue surrounding the piriform aperture.



**Fig. 2** The nasal width measured 6 months postoperatively, with increased distance between the ala.

In order to minimize this unwanted effect, we performed on each case cinch suture. The cinch suture is usually utilized in bimaxillary orthognathic surgery. This surgical decision was held based on literature data that shows the importance of the cinch suture along with the V-Y suture. We used in order to maintain stable results Vicryl 3-0 as suture material.

We consider the opening of the alar base to be dependent only partially on the skeletal modifications that were induced surgically. This effect seems to be close linked to the dissection and elevation of the soft tissue as well as

the enlargement of the lateral wall base of the piriform aperture.

All patients presented after surgery modifications at the external nose level and at the upper lip. We observed a growth in dimension in female patients (59, 4%) in comparison to the male patients analyzed and measured (48, 7%). These modifications are not predictable.

Postoperative the presented patients show a growth of the alar base from 3, 12 mm to 3, 48 mm and from 3, 43 mm to 3, 65 mm.

The nasal-labial angle has grown with about 2 degrees.

Even if facial modifications do occur, the esthetic result was pleasing

for the patients and the final outcome was appreciated as good.

## CONCLUSIONS

Based on the data and results gathered, we can conclude the following:

1. Increasing of the alar base after orthognathic interventions, although we performed cinch suture along with V-Y suture.
2. Widening of the alar base following total maxillary osteotomy with advancement can compromise the fa-

cial aesthetics. Alar cinch suture and its modifications is simple and convenient, means to narrow the alar base.

3. The alar base growth has not been considered by patients as disturbing; quite contrary, they are pleased by the esthetic outcome.
4. The alar base has stabilized after 6 months after the surgery.

## REFERENCES

1. Bertossi D, Albanese M, Malchiodi L et al. Surgical alar base management with a personal technique-the tightening alar base suture. *Arch Facial Plast Surg* 2007; 9:248-51.
2. Nary Filho H, Gonçalves ES, Felix GB et al Evaluation of the facial soft tissues following surgically assisted maxillary expansion associated with the V-Y suture. *Int J Adult Orthod Orthognath Surg* 2002; 17:89-97.
3. Lanigan DT, Mintz SM Complications of surgically assisted rapid palatal expansion: review of the literature and report of a case. *J Oral Maxillofac Surg* 2002; 60:104-10.
4. Byloff FK, Mossaz CF. Skeletal and dental changes following surgically assisted rapid palatal expansion. *European J Orthod* 2004; 26:403-9.
5. Baraldi CE, Pretto SM, Puricelli E Evaluation of surgically assisted maxillary expansion using acoustic rhinometry and postero-anterior cephalometry. *Int J Oral Maxillofac Surg* 2007; 36:305-9.
6. Koudstaal MJ, Poort LJ, Van Der Wal KGH et al. Surgically assisted rapid maxillary expansion (SARME): a review of the literature. *Int J Oral Maxillofac Surg* 2005; 34:709-14.
7. Babacan H, Sokucu O, Doruk C et al. Rapid maxillary expansion and surgically assisted rapid maxillary expansion effects on nasal volume. *Angle Orthod* 2006; 76:66-71.
8. Compadretti GC, Tasca I, Alessandri-Bonetti G et al. Acoustic rhinometric measurements in children undergoing rapid maxillary expansion. *Int J of Pediatr Otorhinol* 2006;70:27- 34.
9. Basciftci FA, Mutlu N, Karaman AI et al. Does the timing and method of rapid maxillary expansion have an effect on the changes in nasal dimensions? *Angle Orthod* 2002; 72:118-123.
10. Ellis E, Zide MF. *Surgical approaches to the facial skeleton*. Lippincott, Williams, & Wilkins, Philadelphia 1994.
11. Northway WM, Meade JB Jr. Surgically assisted rapid maxillary expansion: a comparison of technique, response and stability. *Angle Orthod* 1997; 67:309-20.
12. Racey GL. Surgically assisted rapid palatal expansion: an outpatient technique with long term stability. *J Oral Maxillofac Surg* 1992; 50:114-5.